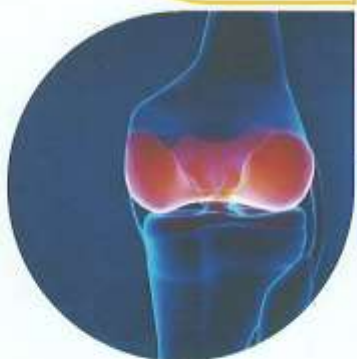


**KISH ISLAND**



**Iranian  
Society of  
Knee Surgery  
Arthroscopy &  
Sports Traumatology**



**5th** Congress of Iranian  
14-17 Feb 2018

**ISKAST**

**Biennial International**



**ABSTRACT BOOK**

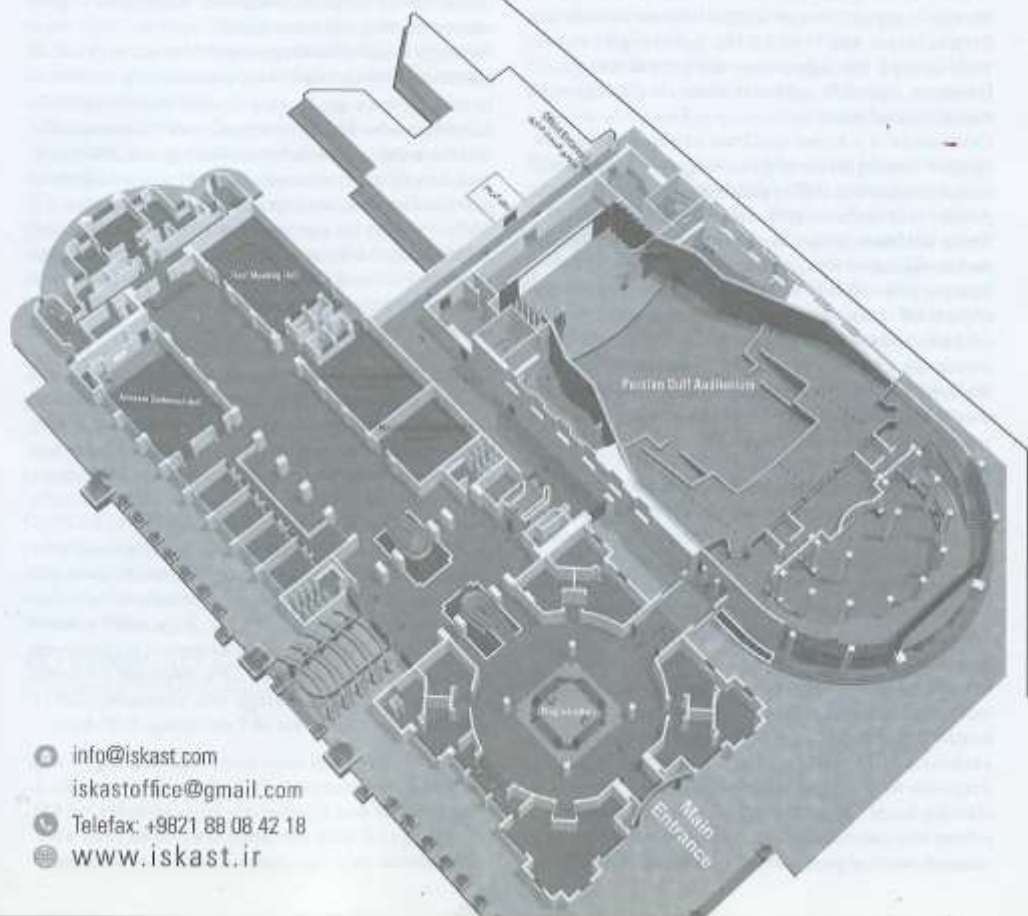


## KISH ISLAND

**5th** Congress of Iranian  
14-17 Feb 2018

**ISKAST**

**Abstract** ▶



- ① [info@iskast.com](mailto:info@iskast.com)
- ② [iskastoffice@gmail.com](mailto:iskastoffice@gmail.com)
- ③ Telefax: +9821 88 08 42 18
- ④ [www.iskast.ir](http://www.iskast.ir)

## ORAL PRESENTATIONS

**1. TITLE : Gentamycin In The Irrigating Solution To Prevent Joint Infection After Anterior Cruciate Ligament (ACL) Reconstruction.**

**Authors :** *Alireza Yousof Gomrokchi, Humidreza Yazdi Ara Nazarian, poopak Hafezi, Aron Lechtig, Philip Hanna, Mohammad Ghorbanhoseini.*

**AIM :** Septic arthritis after ACLR is an uncommon but potentially devastating post-operative complication, the reported incidence rate varies between 0.14% and 1.8%.

The most common predisposing factors to develop SA after an ACLR are: age, BMI, diabetes, smoking previous or simultaneous surgeries, prolonged operative time, long tourniquet inflation time, drain application, graft choice .

Even though prophylactic intravenous (IV) antibiotic is part of the general practice, sometimes it is not enough to prevent this post-operative complication. Prophylactic antibiotic irrigation solutions are widely used during orthopedic surgeries.

However, scientific evidence about its efficacy still remain inconclusive.

Gentamicin is a broad spectrum antibiotic effective against Staphylococci, gram-negative pathogens, Pseudomonas and others pathogens and it has a safe profile, it is thermo-stable and also cost-effective. These attributes makes the gentamicin a great option for intraoperative lavage during ACLR.

The purpose of this study was to investigate the effects of intra-operative gentamicin irrigation solutions and the probability of its usage as a means to prevent SA after arthroscopic ACL reconstruction.

We hypothesized that gentamicin irrigation solutions would reduce post operative infection rate after arthroscopic ACL reconstruction.

**METHODS :** This is a retrospective cohort study of patients who underwent arthroscopic ACL reconstruction with hamstring tendon autograft, in a University Hospital over a 7year period from Feb-2008 to Jan 2015 .

In this study gentamicin added to the normal saline solution was compared versus simple saline solution as an intra-articular irrigation liquid during arthroscopic ACL reconstruction.

Patients were divided in two groups; Group 1 (Saline) included patients who underwent ACL reconstruction with a hamstring tendon autograft, received preoperative IV antibiotics (Cephazolin, 1 gr), and intra-articular irrigation with normal saline solution (0.9 % sodium chloride) during surgery. Group 2 (Gentamycin) Included patients who underwent ACL reconstruction with a hamstring autograft, received preoperative IV antibiotics (Cephazolin,

1 gr), and intra-articular irrigation with gentamicin (80 mg/L) added to the normal saline solution(0.9 % sodium chloride) during surgery.

Patients who required a simultaneous partial meniscectomy were included in the study. Exclusion criteria were: 1) Patients who had a history of chronic infection near the same knee, 2) those who had previously undergone ACL reconstruction and required revision, 3) those who required simultaneous osseotom meniscal repair, cartilage reconstruction, or other knee ligament reconstructions, 4) those who had open procedures, and 5) patients with IV drug addiction, alcoholism, steroid use, diabetes or immune deficiency.

All surgeries were done by the same senior surgeon with the same protocol for preparation, draping, equipment, and surgical technique.

The institution protocol for preoperative IV antibiotic is a dosage of Cephazolin (1 g) 30 min before incision. In case of allergy to the cephalosporin, vancomycin (1 g) or clindamycin (600 mg) is considered.

No allergy to cephalosporin was reported in this study and all patients received Cephazolin (1 g) preoperatively.

In both groups a quadrupled Gracilis-Semitendinosus hamstring tendon autograft was used for ACL reconstruction. In order to define septic arthritis following an ACLR one of the following parameters were used : 1) positive culture or positive Gram stain sample, 2( purulent aspirate, 3 ( PMN >90 % in the aspirate, 4) WBC cell count aspirate, 2(75%<100,000 in the aspirate, or at least two of these parameters: 1) turbid WBC cell count, 4) glucose level in the aspirate lower than 50% of serum level, 5) CRP value >150 mg/dl on day 3 or >20 mg/dl on day 15.

**RESULTS :** 1556 patients met the inclusion criteria of our study; 180 patients in Saline group and 1376 patients in Gentamycin group. 3 patients from Saline group and 89 patients from Gentamycin group were excluded due to loss of follow-up, so at the end a total number of 1464 patients were evaluated. The mean follow up was 33.7 months (range 12-83 months).

A total of seven postoperative septic arthritis cases were documented in both groups through the follow up period (incidence: 0.4 %); four of them were reported in Saline group, giving an incidence of 2.2%, diagnosed 1-8 weeks after the surgery. Three SA cases were reported in Gentamycin group, giving an incidence of 0.23%, diagnosed 2-8 weeks after the surgery. The average time to presentation of symptoms after surgery was 24.7 days (range 8-57 days).

**DISCUSSION :** The most important finding of this study was incidence rate of SA after arthroscopic ACL reconstruction was significantly lower (p-value < 0.05) when irrigated with gentamicin solution than with saline solution only. This study can show that Gentamicin

irrigation solution has a protective effect against SA development after arthroscopic ACL reconstruction. In this retrospective cohort study on 1464 patients who had ACL reconstruction with hamstring autograft, a total of 7 patients developed SA. Four patients from SALINE group (2.2%) and 3 from Gentamicin group (0.23%).

Little has been reported about the prevention of SA following an ACLR. Precautions that are usually used to avoid this complication are using prophylactic antibiotic before surgery and limiting hair removal. Antibiotics selected for surgical prophylaxis should cover microorganisms that usually cause infection, must have an accepted spectrum of side effects, be relatively inexpensive, and should not readily lead to microbial resistance [34]. Although effective in other surgical fields, intravenous antibiotic prophylaxis often fails to prevent septic arthritis after ACLR due to poor vascularity of hamstring tendon autograft and its low levels below the required minimum inhibitory concentration. In our study we found 2.2% postoperative infection rate in the Saline group, which was significantly higher than the Gentamycin group, and also was higher than infection rate reported in previous studies.

Although amino-glycosides has a narrow therapeutic index, using gentamicin as a lavage solution in a low dose and for a limited time (45-70 min) reduces the probability of side effects occurrence. None of the evaluated patients had renal problems, and we encourage studying the effect of This study has some limitations. First the possible toxic effect of gentamicin on human cartilage based on dosage and exposure time was not evaluated and needs more study. Second limitation is that the exact diagnostic criteria to diagnose acute versus late infections has not been well defined in the literature. In this study we used the same criteria for all cases, the groups were not comparable in terms of group size, retrospective design, low-grade infections without any clinical symptoms used in this study to define septic arthritis clinically.

**CONCLUSION :** Gentamicin irrigation solution has a protective effect against SA development after arthroscopic ACL reconstruction. We suggest evaluating this technique as a mean to diminish the incidence of SA after ACL reconstruction.

**KEYWORDS :** ACL reconstruction; Septic arthritis; Gentamicin; Irrigating solution

**2. TITLE : Midvastus approach has better function in the first three months in comparison to conventional medial parapatellar approach: Clinical trial study**

*Authors : Mohammadreza Minator Sajjadi, Adel Ebrahimipour Seyyed Morteza Kazemi ,Sohrab Keyhani , Aron Lechtig, Mohammad Banasiri .*

**AIM :** The main purpose of this prospective randomized study was to compare the clinical outcomes of the midvastus (MV) approach with the conventional medial parapatellar approach (MPP) for primary total knee arthroplasty.

**METHODS :** 70 knees (70 patients) undergoing total knee replacement. Preoperative objective knee society score evaluated, 35 knees were operated by a MPP and 35 knees were operated by MV approach. Intraoperative and clinical records include time of surgery, time of straight leg raising (SLR), 3rd day postoperative hemoglobin level (g/dl) were evaluated. Patients were followed- up at 1 months, 2 months, 3 months, 6 months, 12month, and objective knee society score was calculated.

**RESULTS :** The knee society score (objective) was significant better in midvastus at 1 months (<0.0001), 2 months (<0.0001), and 3 months (<0.0042), but not significant difference between MV group and MPP group in end of 6th and 1st years of follow-up. The mean decrease in hemoglobin level at Third day after surgery in both groups was not different significantly. The time to straight leg raising (SLR) was significantly less in the MV groups. One wound hemarthrosis in the MV group and one wound discharge in MPP group was seen. There was one patient with wound cellulitis in MPP group.

**CONCLUSION :** The objective knee society score of knee replacement by midvastus approach was better in the first 3 months in comparison to medial parapatellar approach.

**KEYWORDS :** Total knee arthroplasty, parapatellar approach, midvastus approach, knee society score

## ORAL PRESENTATIONS

**3 . TITLE :** Malnutrition In Patients Who Are Candidate For Total Hip And Knee Arthroplasty And Assessment Of Cost-effective And Assessment Of Cost-effectiveness Of Screening Program.  
*Authors : Hojat Hejazi, Hossein Ali Hadi Mohmoud Jabalameli, Abolfaz Bagherifard, Amirshahryar Ariamanesh, Fatemeh Khosravipour.*

**AIM :** Periprosthetic joint infection (PJI) is a devastating complication of total joint arthroplasty and malnutrition is well known risk factor of PJI. Malnutrition causes delayed wound healing, prolong hospital stay and delayed rehabilitation period. The objective of this study was to investigate the prevalence of malnutrition in our patients and to determine underlying factors related. Moreover, we assessed the cost-effectiveness analysis of preoperative screening and treatment of malnutrition in these patients.

**METHODS :** In this prospective descriptive study 178 patients were enrolled after signing the consent form. Patients demographic data and underlying problems were recorded. Patients were evaluated for malnutrition in three different methods. Clinical assessment includes arm circumference <22 millimeter and leg circumference <31 millimeter. Laboratory evaluation including serum albumin level <3.5g/dl, Lymphocyte count <1500 cell/mm<sup>3</sup>, serum transferrin <200mg/dl and zinc <95mg/dl were considered as malnutrition parameters. In the third method we filled Mini Nutrition Assessment (MNA, Nestle) questionnaire. Based on the results, malnutrition prevalence and risk factors were determined. Data from the study were analysed in SPSS version 22. For determination of malnutrition prevalence and underlying risk factors chi-square test was used.

**RESULTS :** Mean age of the patients was 66 (+7.9) years and 82% were female. Based on laboratory finding 76 out of 178 patients (42.6%) had malnutrition. According to clinical assessment (arm and leg circumference) 15 patients (9.5%) had malnutrition. With mini nutrition assessment (MNA) form 1 patient (0.6%) falls in malnutrition group and 15 patients (9.5%) were at risk of malnutrition. Unless BMI of less than 18kg/m<sup>2</sup>, we could not able to find other risk factors of malnutrition in our patients. Cost-effective analysis showed 95% reduction in costs with preoperative screening program.

**DISCUSSION & CONCLUSION :** Because of high prevalence of malnutrition in this group of patients and due to very cost-effective screening protocol, it seems to be beneficial to find malnourished patients to reduce post-operative complications. Studies with large population is required to identify risk factors of malnutrition.

**KEYWORDS :** Knee and hip arthroplasty, malnutrition, cost-effectiveness.

**4. TITLE :** Different References For Valgus Cut Angle In Total Knee Arthroplasty.

*Authors : Arash Amiri, Hamidreza Yazdi Ali Torkaman, Ara Nazarian, Jim S Wu Margaret Babikian, Mohammad Ghorbanhosseini.*

**AIM :** The valgus cut angle (VCA) of the distal femur is determined based on the angle between the anatomical and mechanical axes of the femur. The mechanical axis is one of the most important factors determining prognosis of surgery. Achieving normal knee alignment in the surgeries of the knee, such as TKA is crucial. VCA is measured on a three-joint alignment radiograph preoperatively. The anatomical axis of the femur can be outlined either by using the full length of the femur or by using the distal half of the femur, which may lead to different results. Several studies have shown that varus or valgus malalignment are associated with unfavorable outcomes after TKA. To reduce the failure rate of this procedure, normal mechanical balance in the joints must be restored. The aim of this study is to compare the VCA of distal femur determined by anatomical axis of the either full length or distal half of the femur in both normal and varus aligned femurs. We hypothesized that the VCA would be different based on these two definitions of the anatomical axis and this should be considered in pre-operative planning.

**METHODS :** From Jan 2011 to Dec 2013, 194 subjects were recruited from the outpatient clinic located in our university hospital. Patients with full length alignment view radiographs who met the inclusion criteria for this study were enrolled. In order to determine the mechanical Lateral Distal Femoral Angle (mLDFA), the center of the femoral head was identified using the PACS software (Clear Canvas Workstation Version 2.0.12729.37986 SP1). Next, a line was drawn tangent to the articular surface of the femoral condyle, and another was drawn from the center of the femoral head to the deepest part of the

intercondylar notch in the distal femur. The angle between intersection of these two lines is called mL DFA, which determines whether the femoral shaft is classified as normal, varus or valgus.

Femurs were categorized as normal if the mL DFA was between  $85^\circ$  to  $89^\circ$ , in varus if mL DFA was greater than  $89^\circ$  or in valgus if the mL DFA was less than  $85^\circ$ . Those with valgus femurs were excluded. Other exclusion criteria were deformity of the lower limb, previous surgery on the lower limb or presence of radiographic signs for osteoarthritis.

To outline the anatomical axis of the full length of the femur, a point equidistant from medial and lateral cortices of the femur, 1-3 cm distal to the lesser trochanter, was marked. Then a line was drawn from this point to the deepest point of the intercondylar notch, which created an angle between the mechanical and anatomical axes of the full length of the femur. We named it Angle 1.

To outline the angle between the mechanical axis of the femur and the anatomical axis of the distal half of the femur, which we named Angle 2, we marked the midway between the proximal femoral head to the most distal articular surface. At this level, we marked the point in the middle of medial and lateral cortices and then drew a line from this point to the deepest point of the intercondylar notch. This line represents the anatomical axis of the distal half of the femur. The angle between this line and the mechanical axis of femur was measured.

All measurements were performed by two orthopedic surgeons using a DICOM viewing software (PACS). Angles 1 and 2 were compared using t-test in normal and varus aligned cases.

**RESULTS :** Ninety-seven consecutive subjects with normal and 97 consecutive subjects with varus aligned femurs were included in this study. The mean age was  $35.51 \pm 12.15$  years old (range: 18 to 65 years). 55.6% of the subjects were female ( $n=108$ ) and 44.4% of the subjects were male ( $n=86$ ).

The average lateral distal femoral angle (LDFA) in the normal femoral axis and the varus groups were  $87.54^\circ \pm 0.86^\circ$  and  $90.89^\circ \pm 0.88^\circ$  respectively. There was a significant difference in mean LDFA values between the normal and varus groups ( $p=0.001$ ).

In the normal aligned femur group the mean values for angles 1 and 2 were  $5.05^\circ \pm 0.76^\circ$  and  $3.62^\circ \pm 1.19^\circ$  respectively, which were statistically significant ( $p\text{-value}=0.0001$ ). In the varus aligned femur group, the mean values of angles 1 and 2 were  $5.42^\circ \pm 0.85^\circ$  and  $4.23^\circ \pm 1.27^\circ$ , respectively, and the differences

were significant as well ( $p\text{-value}=0.0047$ ). There was no correlation between angles 1 and 2 in relation to the length of the femur in patients with varus aligned femurs ( $p = 0.50$ ) or for patients with normally aligned femoral axes ( $p\text{-value} = 0.70$ ).

**DISCUSSION :** This study shows that utilizing either the anatomical axis of the full length of the femur or the anatomical axis of the distal half of the femur would result in different valgus cuts in TKA, in both normally aligned and varus femurs. The mean value of angle 1 was  $5.05^\circ \pm 0.76^\circ$  and the mean value of angle 2 was  $3.62^\circ \pm 1.19^\circ$  in normal aligned femurs, which were statistically different ( $p\text{-value}=0.0001$ ). In varus aligned femurs, the mean value of angle 1 was  $5.42^\circ \pm 0.85^\circ$  and for angle 2 was  $4.23^\circ \pm 1.27^\circ$ , which were also different ( $p\text{-value} = 0.0047$ ).

TKA systems use 2 types of intramedullary guide, short and long. The short guides follow the path of the anatomical axis of the distal half of the femur, which is different from the anatomical axis of the full length of the femur. So, it is crucial that the surgeons consider the system they are working with, and choose between the anatomical axis of the full length and the distal half of the femur according to the length of the intramedullary guide of the system they are using in pre-op planning. Limitations should be addressed in future studies.

The distinctive aspects of this study compared to Moreland et al and Oswald et al were the large number of subjects and including 2 separate populations with normal and varus aligned femurs. Another important difference between this study and previous similar studies was that we considered the deepest part of intercondylar notch as the reference point for anatomical axis. This point is the entry point of the intramedullary guide and is more relevant in pre-op and intra-operative planning rather than previous methods.

In this study there were some limitations. We didn't include valgus knees. Also we didn't investigate the sagittal alignment of the limb which may have some effects. We think these 2.

**CONCLUSIONS :** Based on this study, the two different measurements of anatomical axis of the femur lead to different results in both normal and varus-aligned femurs. This difference should be considered in determination of the valgus cut angle on pre-operative radiographs and be adjusted according to the length of used intramedullary guide intra operatively.

**KEYWORDS :** Valgus cut angle; Total Knee Arthroplasty; Anatomical axis; Preoperative planning

## ORAL PRESENTATIONS

**5 . TITLE : One-stage Surgical Treatment For Concomitant Rotator Cuff Tears With Shoulder Stiffness Has Comparable Results With Isolated Rotator Cuff Tears: A Systematic Review.****Authors : Sohell Sabzevari, Amirreza Kachooei Juan Giugale, Albert Lin.**

**AIM :** Rotator cuff tears with concomitant adhesive capsulitis is a challenging clinical scenario. Addressing preoperative adhesive capsulitis prior to rotator cuff repair is sometimes advocated but whether this approach improves outcomes is controversial. Some authors have reported satisfactory outcomes after one-stage treatment of rotator cuff repair and simultaneous manipulation under anesthesia, with and without capsular release. In this systematic review, we compare range of motion and functional outcomes of combined surgical treatment of RCT and adhesive capsulitis versus the treatment of isolated RCT without shoulder stiffness.

**METHODS :** Following the Preferred Reporting Items for Systematic Reviews and Meta-Analyses guideline, we searched the databases including MEDLINE, EMBASE, Cochrane Library, and Scopus using the keywords of "shoulder stiffness" and/or "adhesive capsulitis" and/or "frozen shoulder" with "rotator cuff tear". We included studies that only met all 3 following criteria: 1) compared the two arms of isolated RCT versus RCT with concomitant adhesive capsulitis, 2) received no physical therapy prior to surgery, and 3) available reported data of pre and postoperative range of motion and functional outcomes at 3, 6, and at least 12 months after surgery.

**RESULTS :** Four level III studies met the inclusion criteria. The nonstiff group (isolated RCT) underwent rotator cuff repair (RCR) with/without acromioplasty in all studies while stiff groups (RCT with concomitant adhesive capsulitis) underwent RCR, acromioplasty, manipulation under anesthesia with/without capsular release. There were significant differences in preoperative ROM (forward flexion, external rotation at side, and internal rotation at 90° abduction) between stiff and non-stiff groups. 3 studies revealed that at 3 months follow up there were no significant differences in ROM (forward flexion, external rotation at side, and internal rotation at 90° abduction) between stiff and non-stiff groups [1-3] In one study there was no significant differences in forward flexion between stiff and non-stiff groups at 3 months and no significant differences in external rotation at side and internal rotation at 90° abduction at 6 months

follow up [4]. At final follow-up, there were no statistical differences in all ROM between the 2 groups. There was no significant difference between the 2 groups when comparing pre and post-operative outcome scores including visual analogue scale pain, Constant score, modified American Shoulder and Elbow Surgeon, and UCLA scores. All scores improved at the final follow-up in both stiff and nonstiff groups. Retear after one year was reported in two studies showing higher rates in the nonstiff group. No complications needing reoperation was reported in any of the studies.

**DISCUSSION & CONCLUSION :** Concomitantly treating rotator cuff tears and adhesive capsulitis in one stage has comparable results to the treatment of rotator cuff tears in patients without preoperative stiffness. A physical therapy regimen prior to surgical intervention may not be necessary.

**KEYWORDS :** Rotator cuff tear/ stiffness/ One stage treatment.

**6 . TITLE : The Effect Of Patella Refurcaing In Total Knee Arthroplasty.****Authors : Amir Khorami, Mohammad Fakharian Abolfaz Bagherifard.**

**AIM :** Patella resurfacing in TKA remains controversial. The aim of this study was to compare outcomes following TKA with patella resurfacing with those following TKA without patella resurfacing

**METHODS :** Between 2002 and 2012 ,136 patients that equal 160 knees(some patients had TKA for both knees) with osteoarthritis who met the selection criteria and underwent TKA were randomly divided into 2 groups : patella replacement in 80 cases ,and didn't replacement in 80 patients .There was no significant difference in age , osteoarthritis grade, prosthesis and surgery technique. After at least 12 months of operation ,WOMAC index method were used to assessment the effect of the patella resurfacing.

**RESULTS :** The mean age was 64 years old.(range :55-80). There were 135 women and 25 men in the study .The mean duration of follow up was 7 years (range 1-10 ).There were no difference between 2 groups in pain (p=0.736), Stiffness (p=0.646),Difficulty (p=0.846),and total score (p=0.558)

**DISCUSSION & CONCLUSION :** Clinical outcomes for patella nonresurfacing are similar to those patella resurfacing in TKA.

**KEYWORDS :** Osteoarthritis, Total Knee Arthroplasty, Patella Resurfacing

**7. TITLE : Modified Anatomical Reconstruction Technique for Chronic Acromio-Clavicular (AC) joint dislocation.**

*Authors : Hamidreza Aslani, Fateme Mirzaee Shahin Salehi, Zohreh Zafarani.*

**AIM :** Acromioclavicular(AC) joint injuries are common and often seen in contact athletes, often resulting from a fall on the tip of the shoulder with the arm in adduction. Chronic AC joint instability involves changes in the orientation of the scapula, which caused kinematic changes that might result in chronic pain and discomfort in the shoulder region. Several surgical methods for the management of patients with chronic AC joint instability have been described.

**METHODS :** Due to chronic AC joint dislocation, 3 patients underwent anatomical ligament reconstructions with allograft tendon grafts and in this technical note, we explain this modified method.

**RESULTS :** The outcomes were Disabilities of the Arm, Shoulder and Hand (DASH), pain (Visual Analog Scale, VAS), cross-arm test, stability of the AC joint, and patient Satisfaction. Outcomes evaluated after a mean of 1 year and all of them showed significant changes.

**DISCUSSION & CONCLUSION :** The goal of reconstructive surgery is to remove pain and discomfort by stabilizing the AC joint and maintaining, or even improving, shoulder function. Biomechanical studies have demonstrated the importance of anatomical reconstruction of the AC joint in patients with unstable ACJ injuries. This method (anatomical ligament reconstruction with allograft tendon grafts) showed satisfactory results, that patients return to daily activities was faster and joint fixation was achieved. In future studies, randomized controlled trials with more cases and longer follow-up are supported to investigate the modified anatomical reconstruction technique for Chronic Acromio-Clavicular(AC) joint dislocation.

**KEYWORDS :** Chronic Acromioclavicular joint dislocation; ligament reconstruction; anatomical Reconstruction

**8 . TITLE : Mid Term Results Of Arthroscopic Release Of Tennis Elbow, Preliminary Report In Iran.**

*Authors : Hossein Saremi, Mohammad ali Sayedan.*

**AIM :** to evaluate results of arthroscopic treatment of recalcitrant lateral epicondylitis in IRAN.

**METHODS :** 44 patients of recalcitrant tennis elbow were treated by arthroscopic release from October 2012 to June 2015, after at least 6 months of nonoperative management. pain was evaluated by VAS. functional status was evaluated by quick DASH score .mean time of operation and mean time of return to work after operation was also recorded.

gripe strength and pinch strength of the affected limb was measured and compared to other side.

**RESULTS :** 4 patients did not cooperated for complete followup. Mean time of follow up was 16.8 months. VAS decreased from mean of 7.05 preoperatively to 2.3 postoperatively ( $p=0/001$ ). Quick DASH score diminished from 63.18 to 25.68 ( $p=0/001$ ). mean time of return to work was 15.9 days .mean time of operation was 13.8 minutes. gripe and pinch strength of the affected side was not different statistically compared to other side.

**CONCLUSION :** Arthroscopic release of tennis elbow is an effective procedure for treatment of recalcitrant cases in iran in which we donot have a good results of open surgery of lateral epicondylitis.

**KEYWORDS :** Lateral epicondylitis, Tennis elbow, Elbow Arthroscopy.

**9 . TITLE : Rotator Cuff Tear With The Concomitant Long Head Of Biceps Tendon(lhbt) Degeneration: What Is The Preferred Choice? Open Subpectoral Versus Intraarticular Tenodesis.**

*Authors : Mohsen Mardani-Kivi, Sohrab Keyhani, Mohammad Hossein Ebrahimzadeh, Keyvan Hashemi Motlagh, Khashyar Seheb Ekhtiyari.*

**AIM :** lesions associated with the biceps tendon are commonly detected during arthroscopic repair of rotator cuff tears. Acquiring a preferable technique to repair both cuff and LHBT lesions was the aim of several recent studies. This study was aimed to compare clinical and functional outcomes of open subpectoral vs. arthroscopic intraarticular tenodesis in patients with reparable large and massive rotator cuff tear associated with LHBT degeneration.

**METHODS :** In this randomized clinical trial, 60 eligible candidates for arthroscopic rotator cuff repair (mean age:  $55.7\pm 6.9$ ) were allocated in control group (open subpectoral: SP) or intervention group (intraarticular: IA). In IA group, anchor suture was used for both rotator cuff repair and LHBT tenodesis. In SP group, after arthroscopic repair of rotator cuff, subpectoral tenodesis of LHBT was performed using interference screw. Patients were evaluated for pain intensity (visual analogue scale) and shoulder function (constant score and simple shoulder test).

**RESULTS :** Both groups were similar with regards to demographic characteristics and preoperative evaluations (all  $P>0.05$ ). The functional status of both groups was improved; however, it was not significantly different between the two groups ( $P=0.1$  and  $P=0.4$ , respectively). Pain intensity had decreased in 2-year follow-up, and the value in pain reduction was similar between the two groups. The patient's satisfaction also was similar in both groups.



## ORAL PRESENTATIONS

**CONCLUSION :** It seems that large and massive rotator cuff tear (tear > 3 cm) associated with LHBT pathologies benefitted from intraarticular or sub pectoral tenodesis similarly and there are no differences in short and mid-term results of these two techniques.

**KEYWORDS :** Rotator cuff tear; open subpectoral tenodesis; arthroscopic intraarticular tenodesis; long head of biceps tendon; shoulder function; pain intensity.

**10 . TITLE :** Simultaneous Reconstruction Of Medial Collateral Ligament And Posterior Cruciate Ligament Via Single Medial Femoral Tunnel : A Modified Technique And Case Series.

**Authors :** Seyed Taghi Nourbakhsh, Mohammad Banasiri, Hamidreza Aslani, Fateme Mirzaee, Mahmoud reza Fayyaz, Zohreh Zafarani.

**AIM :** Medial collateral ligament (MCL) is the most common knee ligament injuries, and lesions associated with the central pivot mechanism injury, such as anterior cruciate ligament (ACL) or the posterior cruciate ligament (PCL) in the multi ligament knee injury should be reconstructed to prevent failure of ACL OR PCL ligament reconstruction. The aim of this study was to evaluate the outcome of simultaneous reconstruction of medial collateral ligament and posterior cruciate ligament via single medial femoral tunnel, with 24 months follow-up period.

**METHODS :** 8 patients with combined PCL/MCL chronic injuries (6 to 12th month from injury) were selected. The patients undergoing simultaneous PCL and MCL reconstruction with Achilles tendon allograft via a single medial femoral condyle tunnel to prevent tunnel collision.

**RESULTS :** All patients achieved a minimum range of motion 105 degrees. The mean extension lag and loss of flexion values compared to the contralateral side was  $0 \pm 2^\circ$  and  $7 \pm 10^\circ$ , respectively. Our results included 14 reconstructions with two failure (14.2%) ,one failures one in the PCL (7.1%) and one in the MCL (7.1%), . In the last clinical assessment, the mean IKDC subjective score was  $69.6 \pm 15.3$  ( $P=0.001$ ) in comparison to preoperatively. The Lysholm score improved from a mean of 39.02 (28 to 53) to was 81.1 (59-99) ( $p = 0.0001$ ) and the median Tegner score was from a mean of 2.6 (1 to 4) to 5 (2-7) ( $p = 0.0001$ ).

**DISCUSSION & CONCLUSION :** Combined reconstruction of MCL/PCL with Achilles allograft via single medial femoral condyle can be avoided by tunnel collision and patients that treated with this technique had good results.

**KEYWORDS :** knee reconstruction, medial collateral ligament, posterior cruciate ligament.

**11 . TITLE :** Presoaked Teicoplanin And Cefazoline Autograft And Suture Materials Prevent Infection In Acl Surgery.

**Authors :** Amirmohammad Navali .

**AIM :** The purpose of this study was to investigate whether presoaking of suture materials and autografts (BPTB and hamstring) with teicoplanin and cefazoline solutions prevent joint infection following arthroscopic ACL reconstruction.

**METHODS :** In this prospective study 823 consecutive patients who underwent anterior cruciate ligament reconstruction (ACLR) during a 4-year period were enrolled. In the initial 2-year period, 385 patients (group 1) underwent ACLR with a cefazoline-pres soaked autograft and in the subsequent 2-year period, 438 patients underwent ACLR with a teicoplanin-pres soaked autograft (group 2) with preoperative IV cefazoline in both group. Presoaking involved wrapping autografts in a sterile gauze, which had been previously saturated with 5-mg/mL cefazoline or 2-mg/mL teicoplanin solution and soaking the suture materials in the same solutions in the beginning of the operation. The autografts were irrigated once again before final implantation.

**RESULTS :** In the post-operative period 819 out 823 patients were available for study and during the one-year follow-up no infection (0%) was recorded.

**CONCLUSION :** Prophylactic teicoplanin or cefazoline presoaking of autografts (hamstring or BPTB) and suture materials during ACL reconstruction reduced the infection rate in this series compared with other reported studies with IV antibiotics alone.

**KEYWORDS :** ACL reconstruction, infection, antibiotic, soaking .

**12 . TITLE :** Relation Of Generalized Ligamentous Laxity Score With Restriction Of Range Of Motion After Bankart Repair And Remplissage Procedure.

**Authors :** Hossein Saremi .

**AIM :** to evaluate if ligamentous laxity score has a role in restriction of range of motion after combined bankart repair and remplissage procedure.

**METHODS :** we examined all patients with anterior shoulder instability who underwent arthroscopic bankart repair with and without remplissage procedure .we not only evaluated and compared results of the operation in both groups but also determined Beighton score of laxity in all patients and compared beighton score in those with or without restriction of range of motion.

**RESULTS :** the study included 46 patient with bankart repair and 34 patients with bankart repair and remplissage procedure ,with 2years mean time of follow up ,there was no redislocation, restriction of external rotation was 8.8% in remplissage group compared to 7.7 % in bankart group without remplissage( $p=0.96$ ), average external rotation restriction was 5.50 and 5.33 degree respectively( $p=0.66$ ), mean and SD of beighton score was  $2.00\pm 1.89$  and  $2.78\pm 2.12$  in patients with and without restriction of range of motion.( $p=0.33$ )

**CONCLUSION :** remplissage procedure dose not affect amount of restriction of external rotation of patients who undergoe bankart repair ,potential for restriction of range of motion is not related to laxity score so we recommend remplissage procedure for all bankart repairs.

**KEYWORDS :** Generalized ligamentous laxity, Range of motion, Bankart repair, Remplissage .

### 13 . TITLE : Novel Bioabsorbable ACL Reconstruction Screws.

*Authors : Javad Ebrahimzadeh,  
Mohammad Hossein Ebrahimzadeh .*

**AIM :** Biodegradable polymers are becoming more popular as implant materials in orthopedics. One of these popular orthopedic implants is biodegradable fixation screws which have been utilized for the fixation of anterior cruciate ligament (ACL) grafts to secure the graft in the femur and tibia. To overcome some of the potential problems attributed to metallic interference screws, the biodegradable screws were generated. Some of these problems include the necessity of a secondary surgery as well as distorting the magnetic resonance imaging (MRI). Moreover, the metal screws can lacerate the graft and it can also hinder future reconstructions. In this paper, engineering of a novel formulated of biodegradable nanocomposites composed of biopolymer blends, as matrix materials and sol-gel derived osteoinductive filler content was pointed. The formulated optimum composition of nanocomposites possesses best condition for initial mechanical properties of ACL reconstruction screws application. The senior goal is to develop materials with optimum initial mechanical properties and improved cell responses with the prospect of using them as ACL reconstruction screws.

**METHODS :** Different nanocomposites made of a polymer blend PCL and various amounts of a sol-gel derived bioactive glass nanoparticles (BGn) (1, 3 and 6 wt%) were prepared using a solvent evaporation technique. In this respect, firstly, the polymer blends with different compositions was obtained by adding PDLA as polymer matrix into chloroform medium following the addition of different amounts of PCL phase as a soft component. Secondly, in order to prepare the

nanocomposites, the blend composition with favorable properties was selected and different osteoinductive filler phase was introduced into the polymer blends. For this purpose, the homogeneous suspension of BGn was added to the polymer blend containing optimal composition which evaluated previously and was further sonicated to ensure better homogeneous distribution of the nanoparticles. After homogenization, the mixture was poured into a flat glass plate to obtain a flake, dried and then in a vacuum oven to remove the chloroform medium.

**RESULTS & DISCUSSION :** The characterization of BG nanoparticles confirmed that the sol-gel derived products have amorphous nature, heterogeneous surface with random-sized particles ranging from 30 nm to 150 nm and high surface area as well as 121 m<sup>2</sup>/g (Not shown). Fig 1(a-c) shows the SEM micrograph of blends reflecting the distribution of soft phase of polymer as spherulite particles with homogenous dispersion feature throughout the polymer matrix. These biphasic morphologies present the immiscibility of the PCL in PDLLA matrix due to the different solubility parameters of these polymers. Moreover, the high magnified image of PDLLA/PCL blend suggested the good interfacial adhesion between PCL and PDLLA phases (Fig 1(d-e)). Fig.2 indicated the tensile stress, flexural stress and elongation variation of neat PDLLA and PDLLA containing 10, 20 and 30 wt% PCL phase. The maximum yield stress value belongs to the neat PDLLA with about 4% elongation at the break point. By increasing the PCL content from 10 to 30 wt%, the yield stress decreases while the elongation at the break point increases considerably.

**CONCLUSION :** The novel formulated PDPDLA/PCL/BGn nanocomposites showed an improved mechanical behavior which the compositio:position contains of 3% wt osteoinduct fulfills mechanical requirements for the biodegradable screws in ligament reconstruction.

**KEYWORDS :** PDLLA, PCL, BGn, ACLCL screw, Bioabsorbable .

### 14 . TITLE : Clinical Outcome Of Anatomical Arthroscopic Posterior Cruciate Ligament Reconstruction With Achilles Tendon Allograft .

*Authors : Omid Shahpari,  
Mohammad Hossein Ebrahimzadeh .*

**AIM :** good clinical outcome and daily functions after anatomical arthroscopic posterior cruciate ligament (PCL) reconstruction is goal standard in this surgery but to date, there are challenging issues between orthopedic surgeons regarding patient selection, graft selection and technique selection.

## ORAL PRESENTATIONS

**METHODS :** we retrospectively reviewed the patients who underwent anatomical arthroscopic PCL reconstruction with achilles tendon allograft from 2007 to 2013. 32 eligible patients who had met our inclusion criteria were examined regarding knee stability by clinical examinations and KT 2000 arthrometer and were also evaluated regarding variables related to their health and knee status with a mean 36 months follow-up.

**RESULTS :** 30 patients were male and the other 2 cases were female. the mean age was 30 ±8 years old and mean BMI amount was 25 ± 2. 4 patients had normal tests , 11 had near normal 9 abnormal and 8 severely abnormal result in testing by KT2000. final KOOS score was 73.92± 15. Mean lysholm score was 79.50± 17. Mean International Knee Documentation Committee ( IKDC) score of this study was 58.20 ± 10.47.patients who had concomitant partial meniscectomy had significantly lower IKDC scores (p<0.01).mean kapala score was 80.06± 16.

**DISCUSSION & CONCLUSION :** The use of achilles tendon allograft besides the most important part of the treatment which is the surgical technique would yield to excellent results in PCL reconstruction both subjectively and objectively. In addition, patient selection and surgeon's experience should be considered in determining the treatment plan for the patients.

**KEYWORDS :** PCL; Reconstruction; achilles tendon.

**15 . TITLE : Total Knee Replacement In Varus Knee: What Measurement Really Matters? Introducing A New Classification System .**

*Authors : Hojat Askari, Seyed Mohammad Javad Mortazavi, Ahmad Ramezanzpoor, Mohammad Javad Dehghani.*

**AIM :** o present a new classification and surgical technique patients with Varus deformity Candidate for total knee replacement .

**METHODS :** In this study, 102 patients (including 122 knees) were studied. 68% of patients were female and the rest were male. After the initial pre-op planning, Patients were operated based on the medial defect and lateral laxity (degree of JCA and lateral trust) and finally classified. Then cut-off size of the lateral tibia was determined based on new classification.

**RESULTS :** In the present study, Varus varies in the range of 9 to 42 degrees. According to the new classification system,13 % of patients were in group 1 ( without defect -without laxity) , 18 % in group 2 ( without defect - with laxity) , 27 % in group 3( with defect - without laxity) , 42% in group 4 (with defect - with laxity). 13 % of patients needed medial release. all patients were placed under the TKA with PS system. The size of the liner in 78% of patients was 10 mm, 17%, 8 mm and Other were larger sizes.

**DISCUSSION & CONCLUSION :** According to the analysis, in patients with same JCA and same lateral trust, those without bony defect will need more medial soft tissue release. So we suggested in those patients, lateral tibial cut should be minimally. The presented classification of varus knee and surgical technique algorithm is a good method to reduce need of extra medial release and also of high thickness of polyethylene.

**KEYWORDS :** Varus Knee, tka in varus knee, new classification.

**16 . TITLE : Posterolateral Knee Reconstruction. Authors : Seyed Taghi Nourbakhsh , Hamidreza Aslani, Fateme Mirzaee , Mohammad Ali Sazegari , Zohreh Zafarani.**

**AIM :** Soft tissue structures of the posterolateral corner (PLC) of the knee are considered as essential to varus, posterior and rotational stability of the knee. Isolated PLC injuries are uncommon, accounting for almost 2% of all acute knee ligament injuries, but are often associated with anterior cruciate ligament (ACL) and posterior cruciate ligament (PCL) tears, or tibial plateau fractures. The frequency of posterolateral injuris associated with ACL tear is as high as 10% and those associated with PCL tear 27%. Various operative techniques to treat posterolateral knee instability have been described. The aim of this review is to describe the key elements of posterolateral corner reconstruction technique and to outline treatment options based on the peer-reviewed literature.

**METHODS :** This review included articles published during 2010 to 2017. Search was performed in databases of Science Direct, PubMed, Google Scholar and ISI Web of Knowledge using OR, AND, NOT between the selected keywords and "tiab" tags.

**RESULTS :** The results of studies show that generally proposed methods of reconstructing the posterolateral corner have centralized on the reconstruction of the popliteus, the popliteofibular ligament, and the lateral collateral ligament. PLC reconstruction should be performed at same time or prior to (is staged procedure) ACL or PCL to prevent early cruciate failure.

**DISCUSSION & CONCLUSION :** Untreated PLC injuries can result in increased forces on the ACL and PCL and also early destruction of reconstructions of these structures. Failure to diagnose and treat a defect of the posterolateral corner in a patient who has a tear of the cruciate ligament can also result in the failure of the reconstructed cruciate ligament. There seems to be a consensus of theory that injury to the posterolateral corner, whether isolated or combined, is best treated by reconstructing the posterolateral corner along with the cruciate ligament injury, if combined.

**KEYWORDS:** knee reconstruction, posterolateral corner, posterolateralknee instability .

**17. TITLE : Tibial Tunnel Preparation In Posterior Cruciate Ligament (PCL) Reconstruction? A New Technique To Lessen The Stress.**

*Authors : Ahmad Ramezanzpour , Davood Jafari, Seyed Mohammad Javad Motazavi, Mohammad javad Delghami, Hojat Askari.*

**AIM :** to introduce a new technical point during preparation of tibial tunnel in PCL reconstruction to reduce the chance of popliteal artery injury and to decrease the duration of the surgery.

**METHODS :** Twelve PCL reconstructions were done. In this method we inserted PCL tibial aimer from lateral portal and we put its tip 8-9 mm below shiny white fibers in PCL facet. Then smooth guide pin was inserted from antromedial tibial cortex and advanced to the posterior cortex but not through it. We stopped advancing the pin just when it touched the posterior cortex. Thereafter reaming was done over the guide pin. As the pin was engaged in the posterior cortex we were sure that it would not run before reamer to the popliteal fossa. We stopped reamer just when its head appeared in the PCL facet. Visualizing reamer is much easier and more predictable than visualization of the pin in PCL facet. Other steps of standard arthroscopic PCL reconstruction was done.

**RESULTS :** CT scan was done for all patients and dimensions of tibial tunnel were satisfactory in all patients. There was no neurovascular injury and duration of the surgery was much less compared to similar procedures that were done under C-arm fluoroscopy.

**DISCUSSION & CONCLUSION :** Preventing penetration of guide pin through posterior tibial cortex before reaming can eliminate the chance of neurovascular injury in popliteal fossa and would decrease the duration of surgery by eliminating fluoroscopy during the process .

**KEYWORDS :** Pcl reconstruction, tunnel preopration.

**18. TITLE : Scapulothoracic Arthroscopy, Indications And Technique .**

*Authors : Mohammadnaser Naderi , Hassan Kethanshokouh.*

**AIM :** The aim of this article is to present the indications and technique of arthroscopy of scapulothoracic joint which is not well known.

**METHODS :** The indications for Scapulothoracic arthroscopy are limited, but it is used in resistant cases of bursitis of medial border of scapula and in snapping of scapula. This technique is used in some rare cases of excess bone in anteromedial of scapula, and benign tumors like osteochondroma of medial border of scapula. For doing

scapulothoracic arthroscopy, the patient is placed in prone or lateral position. The scope is entered from medial portal, and from another superomedial portal the shaver enters the articulation. Then burse of scapulothoracic is shaved and shaving of medial border of scapula with burr is done in required cases. The result of this operation in resistant cases of scapular bursitis and in snapping scapula is very good with high satisfaction rate of patients. The reported cases are limited. We must aware of iatrogenic injury to structures nearby to this joint especially to dorsal scapula nerve and artery that passes just close to medial border of scapula.

**RESULTS :** We did this technique in 4 patients with resistant snapping scapula. The result was good.

**DISCUSSION & CONCLUSION :** Arthroscopy of scapulothoracic articulation is a valuable method that can be used for some problems of this joint. In summary, the scapulothoracic arthroscopy is not a well-known technique, but the result in selected cases is good.

**KEYWORDS :** Scapulothoracic arthroscopy, snapping, scapula.

**19. TITLE : The Posterior Fan-Like Extension of the Anterior Cruciate Ligament's Femoral Footprint Affects the Failure Load.**

*Authors : Soheil Sabzevari , Mostafa Khalilpour, Brandon Marshal, Patrik Smolinski, Monica A Linde, Freddie Fu.*

**AIM :** The purpose of this study is to examine the role of the posterior fan-like extension of the ACL's femoral footprint on the failure load of the ligament. It was hypothesized that at high loads, the posterior fan-like extension of the ACL's femoral insertion plays a significant role in increasing the ligaments failure load.

**METHODS :** Ten fresh frozen, mature porcine knees were tested in this study. Porcine knees were chosen for constancy in age, breed (Hampshire) and size. The knees were dissected of all tissues other than the ACL, placed in a material testing machine at 30° of flexion (full knee extension in porcine) and subjected to anterior tibial loading (60 mm/min) until ACL failure. The knees were divided into two groups (n=5): intact femoral ACL insertion and cut posterior fan-like extension of the ACL. With 90° of knee flexion, a folded border was created between the posterior fan-like extension and the mid-substance insertion of the ACL footprint [3]. The area posterior to the folded border was identified as the posterior fan-like extension of the ACL and was dissected from the femur using a surgical no. 11 blade. The posterior fan-like extension and the mid-substance insertion of the ACL footprint were digitized using a probe (Faro, Inc.) and the areas were measured. Data was analyzed using an independent t-test, and statistical significance was set at p<0.05 .

## ORAL PRESENTATIONS

**RESULTS :** The intact femoral ACL insertion site had an area of  $241.2 \pm 67.4 \text{ mm}^2$  and the posterior fan-like extension of the ACL deficient insertion site had an area of  $122.1 \pm 52.7 \text{ mm}^2$ . The failure (peak) load of the intact ACL insertion site was  $426.41 \pm 124.39 \text{ N}$  and the failure load with the posterior fan-like extension of the ACL deficient insertion site was  $229.76 \pm 66.55 \text{ N}$ . The stiffness (failure load/failure displacement) of the intact femoral ACL insertion site and posterior fan-like extension of the ACL deficient insertion site groups were  $16.2 \text{ N/mm}$  and  $7.1 \text{ N/mm}$ , respectively.

**DISCUSSION & CONCLUSION :** This study found that the effect of the transection of the posterior fan-like extension of the femoral insertion site had a significant effect on the ligament failure load in porcine knees. This may have future application to the selection of graft size, location and shape in ACL reconstruction.

**KEYWORDS :** ACL, Fan like extension, failure load

**20 . TITLE :** Comparing the Satisfaction Rate in Patients with Total Knee Arthroplasty (TKA) Surgery in Two Groups of With and Without Patella Resurfacing.

*Authors : Babak Otonkesh, Hosseyn Farahini, Tohid Safaei , Bahram Boddahi, Negin Hatami .*

**AIM:-** The total knee arthroplasty (TKA) is a surgery which is operated on the lower limb. The most important reasons of the necessity of reoperation of the patients in this surgery include infections or movement of the implants. One of the approaches which there have been many studies about evaluating its results is resurfacing. The purpose of the present study is to evaluate the satisfaction rate (evaluation of the function rate) in the patients who had a TKA surgery with and without resurfacing.

**METHODS :** This is a Randomized Clinical Trial. After determining the input and output standards, 100 patients who were eligible for the test were selected and brought into the experiment. Then the selected patients brought into trial and then underwent TKA. It is noticeable that the patients were selected randomly were divided into two groups (with and without resurfacing of the patella) and the satisfaction rate of both groups was evaluated.

**RESULTS :** The data show that there is no significant difference ( $P\text{-value} < 0.05$ ) between the averages of Total Post Final Knee and Function Score ( $156.33 \pm 36.56$  for 'without resurfacing' and  $156.78 \pm 36.42$  for 'with resurfacing') and the averages of Total Pre Final Knee and Function Score ( $33.42 \pm 19.01$  for 'without resurfacing' and  $34.02 \pm 25.03$  for 'with resurfacing'). Also the results demonstrate no significant correlation between Post Pain standards and these groups ( $P\text{-value} < 0.05$ ).

**CONCLUSION :** This study indicates that resurfacing the patella does not affect the satisfaction of the studied patients and improvement of the studied variables comparing to patella without resurfacing.

**KEYWORDS :** Tka, resurfacing, surfacing, patella, knee.

**21 . TITLE :** Arthroscopic Modified All-inside Lateral Meniscal Tear Repair Using Two Posterior Portal Technical Note .

*Authors : Sohrab Keyhani, Mehran Soleymanha.*

**OBJECTIVS :** The purpose of this study was to evaluate and describe the clinical results and outcomes of arthroscopic repair of bucket handle lateral meniscal tear using posteromedial transeptal portal view and role of popliteomeniscal ligament repair without using cannula. Hypothesis was that this technique can be safe and has good clinical results with low cost of material used in comparison to others techniques such as all-inside fixators.

**METHODS :** Between 2008 and 2014, 15 patients (12 men and 3 women) with symptomatic displaced bucket handle lateral meniscal tear were enrolled in the study after qualification. All patients underwent arthroscopic meniscus repair using transeptal posteromedial portal, with a minimum of a 2-years follow-up. Clinical results were evaluated preoperatively and at final follow-up according to Lysholm knee and IKDC score.

**RESULTS :** Patients were followed up for a minimum of 2 years (range: 24-86 months). Their average Lysholm score improved from  $76.4 \pm 8.3$  preoperatively to  $93.8 \pm 4.1$  at last follow-up ( $p < 0.001$ ). Moreover, their mean preoperative IKDC score improved from  $51.3 \pm 21.3$  preoperatively to  $90.6 \pm 11.2$  at the last follow-up ( $p < 0.001$ ). No patient showed recurrence of symptoms or serious complications.

**CONCLUSION :** This study provides evidence that arthroscopic repair of meniscosynovial bucket handle lateral meniscal tear using transeptal posteromedial portal view and popliteomeniscal ligament repair without using cannula, showed excellent clinical outcomes for repair of symptomatic displaced bucket-handle tears of the lateral meniscus. This technique can be safe and has low cost of material used in comparison to others techniques such as all-inside fixators.

**KEYWORDS :** Arthroscopy-lateral meniscus-repair

**1 . TITLE : Intraoperative Fractures in Total Knee Arthroplasty 9 Practical Recommendations.**

*Authors : Amirshahriar Arjumanesh, Mohammad Hallaghnoghadam, Mohammad Sahlan Ardekani, Mohammad Naghy Tahmassebi, Kazem Noroozy.*

**AIM :** To investigate the literature about this rare complication in knee arthroplasty.

**METHODS :** We reviewed all papers about periprosthetic fractures in the last 10 years in pubmed, medscape, google scholar and focused on management of cases with intraoperative fractures.

**RESULTS :** fractures, surprisingly there are a few paper that talk about this complication. 16 papers were selected. 12 papers were about periprosthetic fractures as a complication after surgery and short talk about intraoperative scenario. 2 papers were as case report and only two as a report of arthroplasty complication in two academic departments. We selected 9 golden recommendations which you should consider to prevent these type of complications, also we provide some solutions to overcome them and handling them safely.

**DISCUSSION & CONCLUSION :** There are so many studies about periprosthetic fractures after TKA but few papers talk about intraoperative fractures around the knee during total knee arthroplasty and few data are available to help what type of fixation lead to best result in long term. Also these type of fractures are uncommon but its improper management can impair survival of prosthesis or at least leads to severe effect on joint function and patient's satisfaction.

**KEYWORDS :** Total knee arthroplasty, fracture, complication, intraoperative.

**2 . TITLE : Interstitial Tear Of The Subscapularis Tendon, Arthroscopic Findings And Technique Of Repair .**

*Authors :Hossein Saremi .*

**AIM :** presenting a new subtle tear of the subscapularis tendon with a specific arthroscopic findings.

**METHODS :** This report describes significant interstitial tear of the subscapularis tendon. This tear looks normal in superior, bursal and articular sides. Then its specific arthroscopic findings as "Air bag sign" and repair technique of the pathology is explained.

**RESULTS :** the special tear was detected by looking at " Air bag sign " movement of the subscapularis tendon.it was repaired with a technique like a PASTA lesion.and in 2 years followup the patient is pain free with normal ROM.

**CONCLUSION :** interstitial tear of the subscapularis tendon should be considered as a cause of shoulder pain as interstitial tear of other rotator cuff tendons.it should be kept into consideration and look for it when abnormal movement of subscapularis is detected.

**KEYWORDS :** Interstitial tear,subscapularis tendon,rotator cuff tear.

**3 . TITLE : A Randomized Prospective Comparative Study Of Four Methods Of Biceps Tendonitis Treatment: Ultrasound, Low Level Laser+Ultrasound, Intra-sheat And Extra-Sheat Corticosteroid Guided Injection.**

*Authors : Mohsen Mardani-kivi, Mohammad-Hossein Ebrahim-zadeh, Ahmad Alizadeh , Alireza Rouhani , Khashayar Saheb-Ekhtlari, Keyvan Hashemi-Motlagh.*

**AIM :** The aim of this study was to compare the therapeutic effects between four methods of ultrasound (US) alone or in combination with low level laser therapy (LLLT) (L/US), intra (InCI) and extra (ExCI) sheath US guided corticosteroid injection in the treatment long head of biceps (LHB) tendonitis.

**METHODS :** In a randomized clinical trial, Patients with LHB tendonitis enrolled in a 4-groups (US,L/US, InCI, and ExCI). Pain using Visual Analogue Scale (VAS) and shoulder performance according to Constant-Murley score (CMS) were evaluated at all five visits before, 1 week, 1 and 3 months and 1 years after treatment (IRCT registration number: IRCT201502257274N11).

**RESULTS :** VAS and CMS scores were improved after treatment in all 4 groups and in all visit in comparison to before treatment. VAS score of InCI group in 1 week's visit was lower than all other groups, but became similar to ExCI groups after this visit and was significantly lower than US group 1 year after treatment. CMS was similar in all visits between InCI and ExCI. In 1 week and 1 month visits, significant differences were seen between injection groups and two other non-injection groups, but in the last visit, CMS of InCI was only significant in comparison to US group.

**CONCLUSION :** Although intrasheath corticosteroid injection under US guidance is an effective method for LHB tendonitis especially in the 1st week after treatment, but extra sheath injection also has acceptable results. Using L/US as a less invasive treatment could be as effective as corticosteroid injection in long term.

**KEYWORDS :** Biceps tendonitis, ultrasound, low level laser, corticosteroid guided injection .

## POSTERS

**4 . TITLE :** Relationship Between Femoral Intercondylar Notch Stenosis And Anatomic Integrity Of Anterior Cruciate Ligament During Total Knee Arthroplasty .

**Authors :** Amir Azimi, Hosseinali Hadi, Mahmood Jabalamoli , Abolfazl Bagheri Fard, Ahmadsreza Behrouzi, Gholamreza Azarnia.

**AIM :** Anterior cruciate ligament (ACL) is one of the most important ligaments for normal kinematic of the knee. During degenerative process of the knee femoral intercondylar notch becomes stenotic and acts as a guillotine to disrupt the ACL. Bi-cruciate retaining knee prostheses were designed to replicate more normal knee kinematics. In preoperative planning detection of functional integrity of ACL has paramount importance for these prostheses. The aim of this study was to evaluate the relationship between radiographic femoral notch width index and ACL anatomic integrity during total knee arthroplasty.

**METHODS :** In this double blinded prospective study 102 patients (102 knees) who were scheduled for total knee arthroplasty were enrolled with inform consent. Knee intercondylar notch radiographic view (tunnel view) was taken in 45 degree of knee flexion for all patients. Femoral notch width index was calculated in this radiograph by one senior orthopedic resident. During arthroplasty procedure integrity of patient ACL was recorded in three categories as intact, attenuated and torn (or absent). Patients were divided in two groups based on femoral notch width index. Equal or more than 0.252 were (A group) and less than 0.252 were (B group). We evaluated relationship between radiographic femoral notch width index and ACL anatomic integrity in these patients. Data were analyzed by SPSS 20.

**RESULTS :** 102 Patients [77.5% female, with average age of  $68.29 \pm 7.22$ , and 24.5% male, the average age of  $74.16 \pm 8.03$ ] were studied. The rate of patients that had intact ACL was 32 (32%), attenuated ACL 29 (28.8%), torn ACL 41 (39.1%). The patients subdivide into A (46.7%) and B (53.92 %) groups . A group include [40.42 % intact ACL, 34.04 % Attenuated ACL, 25.53 % Torn ACL] and B group comprise [23.63 % intact ACL, 23.63 % Attenuated ACL, 52.72 % Torn ACL]. In comparison of A group with B group , there is significant difference in anatomic integrity of ACL, patients in Group B has further prevalence of Torn ACL 52.72 % (p value=0.01)

**CONCLUSION :** Femoral notch stenosis in preoperative radiograph has a good correlation with the integrity of ACL during arthroplasty procedure. Knee tunnel view can be recommended for preoperative planning of patients who are candidate of knee arthroplasty with bi-cruciate retaining prosthesis.

**KEYWORDS :** Anterior cruciate ligament, Total knee arthroplasty, Femoral notch width index.

**5 . TITLE :** Are The Underlying Factors (age, Gender, And Body Mass Index) Involved In The Effectiveness Of Prp Injection In The Treatment Of Knee Osteoarthritis? A Blinded Randomized Study.

**Authors :** Mohsen Maralani-kivi, Mahmood Karimi Mobarakeh, Sohrab Keyhani , Keyvan Hashemi-Modaghal.

**AIM :** To investigate the therapeutic effects of PRP injection plus conservative treatment as intervention group versus normal saline injection plus conservative treatment as control group. We also determined the effects of underlying factors including age, sex and body mass index (BMI) on the therapeutic effects of PRP.

**METHODS :** In this single-blinded randomized clinical trial, all patients aged from 40-65 years with grade 3 of knee OA (moderate grade based on Kellgren-Lawrence radiological classification scale) were evaluated for eligibility. In intervention group leukocyte-poor protocol. All patients in both group were also provided with a conservative protocol including oral Celecoxib 100mg BID for 4 weeks, modifying physical activity and performing physiotherapy (15 sessions). The VAS score, and WOMAC scores were measured prior to treatment and at 1 week, 3 and 6 months post treatment.

**RESULTS :** 60 Patients with the mean age of  $61.6 \pm 6.2$  years (21 men and 39 women) were randomly assigned into each arm. Demographic characteristics (age, gender and BMI) and pre-treatment scores were similar between the two groups. WOMAC score was improved from pre-treatment to first week post-treatment in both groups (from  $54.9 \pm 4.8$  to  $64.4 \pm 5.1$  in intervention group and from  $53.4 \pm 4.3$  to  $62.7 \pm 4.8$  in control groups). It means that PRP+conservative treatment was effective, similar to placebo+ conservative treatment. After adjusting BMI as underlying variable, it was indicated that in the patients with lower BMI, PRP provided better outcome in comparison to conservative treatment alone ( $P=0.014$  and  $P=0.019$ , respectively). Also, comparison of functional scores changes with age as underlying variable demonstrated that younger cases obtained better response from PRP rather than conservative alone ( $P=0.012$  and  $P=0.007$ , respectively).

**CONCLUSION :** PRP seems to be an appropriate choice for treatment of moderate osteoarthritis especially in younger patients and those with lower BMI.

**KEYWORDS :** PRP injection, Knee osteoarthritis, Underlying factors.

#### 6 . TITLE : Prophylactic Intra-Joint Application of Vancomycin in Total Knee Arthroplasty.

*Authors : Arash Sharafat vaziri, Mohammad naghli Tahmasebi Shahin Mirkarimi, Babak Haghpanah.*

**AIM :** Infection after knee arthroplasty is a serious concern of arthroplasty surgeons and various methods are described to reduce the same. Local application of antibiotic can reduce the chance of infection without systemic side effects. The purpose of this study is to evaluate the effect of intraoperative powdered vancomycin on the rates of postoperative prosthetic knee joint infection. The use of intraoperative powdered vancomycin as a prophylactic measure in an attempt to reduce the incidence of knee PJI has not been sufficiently evaluated in the existing literature.

**METHODS :** During the period from Jan 2013 to Jan 2017, 682 consecutive Total Knee replacement surgery cases were performed by the same knee surgeon, at 2 hospitals were this surgeon do his surgeries. One gram of powdered vancomycin was placed in all joints prior to capsular closure. A retrospective operative database and medical record review was performed to evaluate for evidence of postoperative prosthetic joint infection and any vancomycin resistant organism. All the patients had at least 1 year follow up.

**RESULTS :** 6 of the 682 patients were identified as having evidence of postoperative prosthetic joint infection and were operated as two staged revision arthroplasty. *S aureus* was responsible in four cases and *Staph epidemidis* in two cases. Vancomycin resistant staph wasn't found. Infection after two staged arthroplasties wasn't found.

**CONCLUSION :** It seems that intrawound vancomycin in combination with preoperative cefazolin will reduce the rate of Prosthetic joint infection meanwhile vancomycin resistance is not a major issue.

**KEYWORDS :** Prosthetic joint infection Powdered Vancomycin Local application .

#### 7 . TITLE : Platelet-Rich Plasma for Frozen Shoulder.

*Authors : Fateme Mirzaee, Hamidreza Aslani , Seyed Taghi Nourbakhsh, Mahmood Reza Fayyaz, Zohreh Zafarani, Mohammad Ali Sazegari .*

**AIM :** Adhesive capsulitis or frozen shoulder is a common cause of shoulder pain and disability, which is estimated to affect between 2% and 5% of the general population and peaks between 40 and 70 years of age. Several treatments utilized to reduce patients' pain and improve range of motion (ROM). Recent researches have been conducted on Platelet-rich plasma (PRP) injection, as a concentrated source of autologous platelets in blood plasma, contains several different growth factors and other cytokines that can stimulate

healing of soft tissue. Due to the lack of sufficient evidence in this field, the purpose of this case series study was to investigate the clinical results of PRP injection for patients with frozen shoulder, at an average duration of follow up of 25 weeks.

**METHODS :** 44 patients (30 female, 10 male) who were in the phase I or II of frozen shoulder, with a mean age of 52.3 years were treated with PRP. At the first session, we injected two syringe of PRP in the subacromial bursa and intra-articular space (2 centimeters lower than the posterolateral of the acromion and 2 centimeters towards the medial), then we repeated this process after four weeks. In this stage, PRP was injected only in the glenohumeral joint.

**RESULTS :** The average pre-treatment flexion was about 65 degrees, abduction was 70 degrees and external rotation was 22 degrees. Also baseline scores for VAS, DASH, and SF-12 Health Survey questionnaire were 8.4, 65.9 and 26, respectively. After 25 weeks follow-up, all patients showed significant improvement in shoulder ROM, pain, and function ( $p < 0.001$ ) (Table 2). Patients reported 66.7% improvement in pain, 51.6% in DASH score, and 100% in SF-12 Health Survey questionnaire. They were also 65% satisfied with the treatment protocol.

**DISCUSSION & CONCLUSION :** This case series including 44 cases who were in the phase I or II of frozen shoulder to suitable conservative therapy demonstrated clinically and statistically significant improvement in patients' pain and disability outcomes following PRP injection. These results provide support for PRP as a safe treatment protocol that decreases pain and increases upper limb function. Also, it can improve shoulder range of motion. Randomized controlled trials with longer follow-up and comparing the efficacy of corticosteroids, hyaluronic acid, and physiotherapy with PRP are supported to further investigate the influence of PRP injection for treatment of frozen shoulder.

**KEYWORDS :** Frozen Shoulder, Platelet-rich plasma, PRP injection.

#### 8 . TITLE : Management of nonunion in Hoffa fracture: a case report and review literatures.

*Authors : Hojjat Askari , Seyed mohammad javad Mortazavi, Ahmad Ramezanzpoor, Mohhamad javad Dehghani.*

**AIM :** Hoffa fracture is one of the rare occurring fracture of distal femur which can be seen only on coronal plane. Nonunion of Hoffa fracture is very rare and even literature has very few reported cases.

**METHODS :** A 62 years old male sustained Hoffa fracture 3 years ago and developed nonunion of fracture site with pain and restricted ROM of Knee. He was treated with TKA.



## POSTERS

**RESULTS :** Due to very few reported cases of nonunion Hoffa fracture accurate treatment protocol does not exist and revolves around many controversies. Many studies showed that surgeons have adopted different kinds of surgical interventions to treat this type of nonunion

**DISCUSSION & CONCLUSION :** An important question here is which surgical intervention should be implemented? Conservative treatment mostly does not yield favorable outcome and may lead delayed surgical intervention. In patient with good bone density treatment of choice should ORIF and in those with osteoporosis better treated with knee arthroplasty.

**KEYWORDS :** Hoffa fracture, Tka, tka In Hoffa fracture, Hoffa fracture nonunion

**9 . TITLE : Approach to medial tibial defect in TKA The influence of defect area ?**

*Authors : Ahmad Ramezanzpoor ,  
Seyyed mohammad javad Mortazavi, Hojat Askari  
Mohammad javad Dehghani.*

**AIM :** The aim of the study was to introduce a new classification of tibial defect on the basis of depth and area measurements, and also how to manage the defect.

**METHODS :** From 2015 to2016 , 150 varus knee patients with tibial defect had been taken under TKA. All the surgeons took tibial first approach and depth and area of defect after reduction osteotomy were measured using a ruler. All patients were classified on the basis of depth of defect in three groups (I,II,III) and on the basis of area of defect in two groups(A,B).Management of defect was done according to presumed classification and approach to defect.

**RESULTS :** We had 150 varus knee with defect. In this study 64 % of patients were type A (under 40% of medial condyle) and 36 % of patients were type B (above 40%) and also in group I (<5mm depth of defect) most of the patients(85%) were addressed with only cement. In group II( 5-10 mm depth of defect), most of the patients(70%) were addressed with cement and screw. In group III(>10 mm depth of defect ) 75% patients were addressed with cement +screw + stem. During the average one and half year follow up, no sign of failure of fixation of subsidence were seen.

**DISCUSSION & CONCLUSION :** The presented classification and bone loss treatment algorithm is a good method in the sever varus knee with defect. Area of defect is an important point in approach to defect This algorithm, reduces the concern of longevity in prosthetic implant, also more study and long term follow up is needed.

**KEYWORDS :** Tka, Varus kee, Medial tibial defect.

**10 . TITLE : Double-bundle Reconstruction Of Chronic Medial Knee Instability; A Case Series.**

*Authors : Mahsen Mariani-kivi,  
Sohrab Keyhani, Mahmoud Karimi Mobarakeh,  
Zahra Haghighparast Ghadiri-Linudahi.*

**AIM :** Medial collateral ligament (MCL) along with posterior oblique ligament (POL) act in the rotational stability of the knee and resistance against valgus stress. In chronic medial knee instabilities, the two components of MCL (superficial and deep) injuries together with POL tears are considered. In such cases, there are different methods for ligament reconstruction, but, here we aimed to present a specific method of double bundle reconstruction of MCL and POL.

**METHODS :** This retrospective case-series study included 11 male patients with lack of response to non-surgical treatments of grade 3 injuries of MCL who underwent double bundle reconstruction of MCL and POL from 2011 to 2015 in our medical education center. All patients had amateur regular sport activity and complained of persistent MCL laxity and clinical instability. All patients were operated by an expert orthopedist through this novel method with a triangular view graft and using just one screw fixation.

**RESULTS :** Gross malalignment and gait disorders were not seen in any patients during two years' follow-up. All patients showed complete MCL stability without articular line opening in extension and 30 ° flexion in comparison to the other knee. All patients reached full range of knee motion and had negative valgus stress test .

**CONCLUSION :** This reconstruction method, decreases the complications of external device and presents the pressure loads on the knee joint handled by the graft strength its self and not with the fixators.

**KEYWORDS :** Double Bundle reconstruction, knee instability, Medial collateral ligament.

**11 . TITLE : Rotating Hinge Versus Constrained Condylar Knee Replacement: Which One Is Actually More Constrained? A Finite Element Study**

*Authors : Saeid Samieezadeh1, Habiba Bougherara1,  
Mansour Abolghasemian, Darryl Dläna, David Backstein.*

**AIM :** Elevated levels of constraint in knee replacement prostheses have been shown to demonstrate higher loosening rates over time. Specifically, traditional hinge knee prostheses were associated with unacceptably high rates of failure. However, more recent design (rotating hinge prosthesis-RHK) may maintain the perfect coronal plane stability of the pure hinge prosthesis but with the added benefit of excellent rotational freedom. In contrast, the constrained condylar knee (LCCK) prosthesis has little

rotational freedom but is not as constrained as RHK in the coronal and sagittal plane. Since failure of constrained prostheses is linked to transfer of excess stresses to the implant-bone interface we conducted a finite element (FE) study to qualify and compare these stresses rendered to the bone and the bone-prosthesis interface by each of these two modern designs. In addition, since patients that require constrained prosthesis have poor stability due to deficient soft-tissues we simulated deficiency in the medial and lateral collateral ligaments.

**METHODS :** A large left fourth-generation composite femur (model 3406, sawbones, Vashon, WA, USA), which has been developed and validated in previous studies, was used to construct the 3D models. Quantitative computed tomography (QCT) scans were carried out on the sample using a clinical scanner. The images were imported into Mimics software (The Materialise, Leuven, Belgium) and the 3D model of the femur including two bodies representing cortical and cancellous segments was generated and imported into SolidWorks software (SolidWorks Corp., Dassault Systèmes, Concord, MA, USA). The 3D CAD models of RHK and LCCK prostheses, provided by Zimmer (Warsaw, IN, USA) were virtually implanted based on manufacturer-provided instructions. The assembled CAD models were then exported to ANSYS Workbench software (ANSYS Inc., Canonsburg, PA, USA) to produce the FE model. Corresponding material properties were assigned to cortical, cancellous structures as well as prosthetic components and bone cement. Two sets of loads and constraints for two different situations were considered: MCL deficient and LCL deficient knee in full extension. Various linear and non-linear contact types were defined among components based on the behavior of the touching surfaces. Mean (M) and standard deviation (SD) values of shear and von-Mises stresses at the bone-implant interface were obtained in each model and compared to evaluate the level of constraint. Finally the cortical-stem interface areas in the femur and tibia were investigated separately.

**RESULTS :** The results have been summarized in figures 1 to 4. In summary, relatively lower values for shear and von-Mises stresses developed at the bone-implant interface in RHK compared to those in LCCK prostheses in both MCL and LCL deficient configurations. Moreover, lower stress values were found at the polyethylene liner in RHK design as depicted in figure 5. Of interest, it was also observed that MCL deficiency generated higher stress in both femur and tibia in both RHK and LCCK design.

**CONCLUSION :** Lower contact shear stress as in the case of the RHK design results in less micromotion at the interface and may reduce the risk for future loosening of the prostheses. RHK design also results in a more uniform von-Mises stress by showing lower SD at the interface in both femur and tibia. This would

suggest fewer density changes at the periprosthetic regions as a result of bone remodeling. The findings reveal that the RHK design is less constrained compared to LCCK design in full extension boundary conditions. Moreover, the lower polyethylene stresses are due to increased conformity at the tibiofemoral articulation in the RHK design and are likely to reduce wear and osteolysis. Another clinical implication of these findings is the possible superiority of RHK prostheses when treating less severe knee instabilities that are usually treated by the use of LCCK design.

## 12 . TITLE : Intravenous Antibiotics Affect The Profile Of Inflammatory Biomarkers In Healthy Rabbits .

*Authors : Afaneh Saffarian, Fatemeh Chegini, Mohsen Saleghi-Naini, Amir Rostami, Abolfazl Bagherifard, Mohammad Ghazavi, Mansour Abolghassemi.*

**BACKGROUND:** C-reactive protein (CRP) and erythrocyte sedimentation rate (ESR) are inflammatory markers most widely used by clinicians for evaluating the treatment course of osteomyelitis and periprosthetic joint infection. It has been observed that some antibiotics can affect the immune system and lead to increased or decreased serum concentration of inflammatory biomarkers. Specifically, ciprofloxacin and vancomycin, frequently used agents for treatment of musculoskeletal infections, have well established anti-/pro-inflammatory effects. This study aimed to assess the probable confounding effect of these two antibiotics on ESR and CRP of normal healthy rabbits.

**METHODS :** 30 male white New Zealand rabbits were allocated to six groups to receive subcutaneous injection of one of the following seven regimens each 12 hours for 28 days: 1. 60 mg/kg ciprofloxacin 2. 20 mg/kg ciprofloxacin 3. 60 mg/kg vancomycin 4. 20 mg/kg vancomycin 5. 60 mg/kg ciprofloxacin and vancomycin 6. 20 mg/kg ciprofloxacin and vancomycin. Blood samples for measuring ESR and CRP were collected from each rabbit before starting antibiotic administration and in weekly intervals during the study period ending one week after the last administration. Statistical analysis was performed to evaluate the changes in ESR/CRP values inside the groups and among the 6 groups during the course of the study.

**RESULTS :** 2 rabbits (groups 1, 5) died and one more (group 3) developed renal failure and were therefore excluded. There was an obvious rising course for the CRP compared to the baseline values at 1 week after initiation of injections in all groups. The average rise was about 300%. There was little difference between the groups. CRP values started to decline slowly thereafter during the time of antibiotic administration but remained significantly elevated throughout the study period (P value < 0.001). After cessation of injections, there was a sharp decrease toward baseline.

## POSTERS

values in all groups. Graph 1 shows the findings. Changes in ESR values were obtained but still significant. This included an initial rise of ESR values after initiation of the study that remained the same in the following 3 weeks of antibiotic administration and one week after cessation of treatment.

**DISCUSSION :** After surgical treatment of a musculoskeletal infection, parenteral antibiotic administration is usually indicated for a few weeks and the response of the patient is measured with the use of ESR and CRP. It is assumed that any changes in these inflammatory markers reflect the activity of the infection process. However, we found that the biologic effect of two commonly used antibiotics can affect the concentration of ESR and CRP independent to any infectious conditions. Among animals available for clinical studies, rabbit has been recognized as the single animal with closest immune system to human body but magnified inflammatory responses. Although this influence may not be identical in human being or in subjects with musculoskeletal infection, the possibility of this confounding effect must be kept in mind when interpreting the course of inflammatory markers especially early in treatment course of musculoskeletal infections (e.g. after 1st stage revision of a periprosthetic joint infection).

### 13 . TITLE : Management Of Knee Deformities Using Double Osteotomy Technique.

*Authors : Mahmoud Reza Fayyaz ,Hamidreza Aslari, Fateme Mirzazee, Seyyed Taghi Nourbakhsh, Fateme Bahramian, ZohrehZafarani, Mohammad Ali Sazegari Azjzallah Shirvani, AmirFarahanchi .*

**AIM :** The term "double osteotomy" was proposed by Gregosiewicz et al. This technique recommended for the management of knee deformities. The purpose of this report is to express clinical experience with the use of this surgical technique and to describe the long-term follow-up of the patients who were operated on.

**METHODS :** During a 2-year period, 32 subjects with mean age of 42.9±5.3 years underwent Surgery due to genu varum and valgum. Lysholm-Tegner score and KOOS score was used for functional assessment pre-operatively and post-operatively. We used Ramadier's protocol to evaluate the angles of hip, knee and ankle joints. The surgical procedure was that we first started double osteotomy from closing wedge of femoral which was fixed by an AO T-Plate, and then we checked the residual Varus and after that we performed osteotomy of the tibial opening wedge.

**RESULTS :**All patients returned with a good and acceptable performance. The mean Lysholm-Tegner score was 85.6±6.3 points. Also the results show that the mean KOOS score was 91.4±5.7 points. Most patients were satisfied with the results of their surgery. All the angles measured on X-rays had been corrected .

**DISCUSSION & CONCLUSION :**In general, we can conclude that the double osteotomy technique is an acceptable and reliable method. Although this technique is delicate and the difficulties but, finally there are good and satisfying results for patients. Our experience in using this surgical technique showed that this method could be a valid treatment option for the treatment of knee deformities.

**KEYWORDS:** double osteotomy, knee deformities, genu varum, genu valgum.

### 14 . TITLE : Clinical outcome of ACL Reconstruction Using Hamstring Tendon Autograft versus Tibialis Anterior Tendon Allograft.

*Authors : Omid Shafqari ,Mohammadhossein Ebrahimzadeh.*

**AIM :** Despite the large number of anterior cruciate ligament (ACL) reconstructions performed annually, there is a considerable amount of controversy over whether autograft or allograft should be used. The purpose of this study was to evaluate the clinical outcome of ACL Reconstruction using hamstring tendon autograft versus tibialis anterior tendon allograft based on clinical examinations and analysis of KT2000 findings.

**METHODS :** we retrospectively reviewed the patients who undergone anatomical arthroscopic ACL reconstruction with hamstring tendon autograft and allograft tibialis. From 2008 to 2014, 82 eligible patients in autograft and 100 patients in allograft group who had met our inclusion criteria were examined regarding knee stability by clinical examinations and KT 2000 arthrometer.

**RESULTS :**The anterior drawer test was reported to be negative in 19autograft patients (23.18%) and 23 (23%) allograft patients. Thus, the results were not statistically significant. Negative lachman test in allograft and autograft group was in 82 patients (82%)and 67patients (81.8%) which was not statistically meaningful. 10 patients (13%) in autograft and 15 patients (15%) in allograft were found to have positive pivot shift tests. There was no statistically significant difference between the two groups. 85.4 % of autograft and 84% of allograft patients had less than 3 mm side to side difference in active and manual testing by KT2000

**DISCUSSION & CONCLUSION :** The use of quadrupled hamstring tendon autograft and tibialis allograft besides the most important part of the treatment which is the surgical technique would yield to excellent results in ACL reconstruction both subjectively and objectively. The use of hamstring tendon autograft and tibialis anterior allograft yields similar medical results regarding the clinical examination and analysis of KT2000 findings. In addition to the choice of the graft type, the correct choice of the patient and the surgeon's experience are among the factors that help surgeon choose the best surgical technique .

**KEYWORDS:** ACL; Reconstruction; Hamstring tendon, tibialis tendon allograft, KT2000 .

**15 . TITLE :** Late Genu-recurvatum After Total Knee Replacement: Two Cases Report And Review Of Literatures.

*Authors :* Mohammad javad Dehghani ,  
Seyyed mohammad javad Mortazavi ,HojjatAskari,  
Ahmad Ramezanzadeh.

**AIM :** The goal of performing TKA is to obtain a functional ROM. However, sometimes this goal can not be achieved and the patient has one of two complications of flexion contracture or genu-recurvatum.

**METHODS :** in presented paper, two patients who were under primary TKA and After a period with a proper function (4 year in a patient and 1 year in another patient), Have a genu-recurvatum. A re-operation was performed for both patients, and due to wear posterior of the cam of liners, liners was replaced with larger size. In the follow-up of one year in both patients, the knee is stable and functionally good .

**RESULTS :**The genu-recurvatum is a rare condition and in less than 1 % of patients, and early after surgery, can occur due to a number of reasons, for example, a history of neuromuscular diseases or technical mistake during surgery. Until now, genu-recurvatum is not reported late after TKA in English literature, but in presented paper, two patients who were under primary TKA and After a long period with a proper Have a genu-recurvatum. The only important point in both patients that presented is ligamentous hyperlaxity.

**DISCUSSION & CONCLUSION :** ligamentous hyperlaxity can be one of the predictor factors of Late genu-recurvatum after total knee replacement .

**KEYWORDS:** Late genu-recurvatum.tka. Late genu-recurvatum after total knee replacement .

**16 . TITLE :** The Effect Of Body Mass Index On Components Size In Patients With Knee Replacement Surgery .

*Authors :* Gholamreza Ghorbanianjad, Sepehr Shtrouei .

**AIM :** determine the relationship between the size of prosthesis used in knee joint surgery and BMI of patients.

**METHODS :** in this descriptive-analytic study, a census method based on inclusion criteria for medical records of all patients who were undergoing knee replacement surgery in Besat Hospital of Hamedan during the year 1395 in terms of body mass index, age and sex, and size of Tibia and femoral component Were examined. Data were analyzed by SPSS software version 16 .

**RESULTS :**A total of 214 patients were included in this study. In terms of gender, 21.5% were male and 78.5% were female. The mean age of patients was 67.95 years, and the mean body mass index of the patients was 27.98 kg / m2. In terms of component size, most tibia components were of medium size (49.5%) and small femurs (65.9%). There was a direct and significant correlation between Tibia component with body mass index and weight and height by age and sex ( $p < 0.05$ ). However, the correlation between femoral component with weight only at age  $< 65$  years was statistically significant ( $p = 0.02$ ).

**CONCLUSION :**Logistics equipment, especially prostheses, is the cornerstone of this surgical procedure. If you have a general overview of the size of consumable prostheses, you can be more confident. In patients undergoing total knee joint replacement, body mass index, weight and height, in determining the size of the tibia component and weight, determine the size of the femur .

**KEYWORDS:** Body Mass Index, Tibia Component, Femoral Component, TKA.

**17 . TITLE :** Total Knee Arthroplasty In Patient With Tibial Extra Articular Stress Fracture.

*Authors :* Gholamreza Ghorbanianjad,  
Mohammadnaghi Tahmasebi, Keivan Ahadi ,  
Sepehr Shtrouei .

**AIM :** Results of TKA in patient with severe varus deformity and proximal tibial extra articular stress fracture with stem extender .

**METHODS :** In this study from 2013 to 2015 we treated 14 knees(12 patient)with simultaneous proximal tibial stress fracture and severe deformed osteoarthritic varus knees with primary total knee arthroplasty and fit stem extender. All patients were evaluated preoperatively using the Knee Society score, and Knee Functional Score. Weight-bearing anteroposterior knee radiographs and knee lateral radiographs and Standing full-length (hip to ankle) weight bearing radiographs were obtained in all patients. Technetium bone scans were performed in patients whose had pain and point tenderness over tibial bone and radiographs appeared to be normal. Serum calcium, phosphorus, and alkaline phosphatase levels were determined in all patients. A posterior cruciate-substituting design with a press fit and appropriate length stem extender was used in all patients. No bone graft or supplemental plate fixation was used in any of our patients. Early partial weight bearing were advised. Clinical and unctional evaluation using the Knee Society score and knee functional score and standing full-length hip to ankle, knee anteroposterior, and lateral radiographs were carried out for all patients postoperatively at 6 weeks, 3 months, 6 months, and 1 year, and every year thereafter.

## POSTERS

**RESULTS :** we have 14 osteoarthritic knees with tibial extra articular fracture ranging from unicortical lesion (2 knees) to frankly mobile fracture(6 knees) and minimally displaced fracture( 6 knees)three patients with multiple (more than one fracture in ipsilateral ) and two bilateral stress fracture. All of the patients(100%) was female with mean age of 68(range,54-82 years), at mean 28.4 month follow up average Knee Society Score improved from 25.23 to 85.9 and average Knee Functional Score improved from 16.25 to 70.2 ; all patients had union. We did not found any relationship between vitamin D3, calcium and phosphorus serum level with occurrence of stress fracture .

**CONCLUSION :** Difficult primary total knees are common in our country, tibial extra articular stress fracture in severe deformed knees add to treatment challenge. Management of these knees are ill defined. Treatment range from fixation of fracture and delayed TKA to one-stage TKA with stem extender is different. All of our patients managed with primary TKA with stem extender, use of fit stem extender and correction of limb alignment with TKA lead to early arthulation and fracture union, without need to opening of fracture site. All of fracture united in good alignment without any correction loss. serum vitamin D3 ,calcium and phosphor level was normal in all the patients and no relationship between vitamin D3and stress fracture. we learned that in any patient who candidate to TKA and have tenderness over any side of tibial bone must be addressed with Bone scan and whole leg x-ray just before TKA.we recommended correction of severe deformed arthritic knee before occurrence of stress fracture.

**KEYWORDS:** TKA,STRESS FRACTURE,.

**18 . TITLE :** Iranian Joint Registry first Annual report.

*Authors : Hamidreza Aslani,*

*Fateme Mirzoe, Bahare Ahmadinejad.*

**AIM :** The process of hip and knee replacement is an important and growing process in the world. Iran is the thirty-second country in the world, which has an arthroplasty record center.The IJR's Annual Report is an essential pillar and showcases how we monitor the performance of implants, hospitals and surgical technique but also how the registry is driving quality improvement in the orthopaedic sector as a whole. In this paper, according to a report from the Iranian Joint Registration Center from the spring of 2016 to the spring of 2017, we will present a brief report on the one-year activity of this joint registration system.

**METHODS :** The Iranian Joint Registry's maturing dataset by two questionnaires that located on the site (for recording hip joints and for recording hip joints). The IJR's minimal data set is created according to recommendations from the International Society of Arthroplasty Registries (ISAR). The data are collected in the spring of 2016 up to spring of 2017. The questionnaire

consists of 6 steps (Primary information includes demographic information and then specialized information,) which ultimately provided a brief report for surgeons with the information entered.

**RESULTS :** In the One year period, there were 218 hip joints and 564 knee joint records. 564 knee arthroplasty was recorded that 467 cases were female and 290 cases of arthroplasty were performed on the right side. About 505 patients with genu varum were registered that 503 cases have been using Toumaquet. Also, 550 patients had primary total joint replacement surgery with cement that most surgeons used erythromycin in cement. 218 hip arthroplasty was recorded that 117 cases were male and 119 cases of arthroplasty were performed on the right side.

**DISCUSSION & CONCLUSION :** This article provides information on Patient Position, Femur, Acetabulum, Implant Data Cemented, Cage Or Ring and Augmentation Was Used, Approach, Implant Data Head Type, Implant Data Femoral Component Type, Recurvatum Or Flexion Contracture, Genu Varum Or Genu Valgum Detail, Patient Procedure, Patient Specific Instruments, Implant Data Cemented. Development of the Iranian joint registry helps reduce the morbidity as well as reducing the cost of the procedure for patients. We hope to reach to a valid and reliable national registry in a timely manner. Iranian joint registry is designed, which will be developed to form the major source of outcome assessment after orthopedic surgeries. To ensure precise annual reporting the IJR continues to work with many stakeholders including hospitals, industry, and individual surgeons. Joint collaboration of the national organizations is an essential requirement for the advancement of this mission.

**KEYWORDS:** Arthroplasty, Hip, Knee, Iran, Registry national.

**19 . TITLE :** Automated Lachman Test For Objective Assessment Of The Acl.

*Authors : Amir Mohammad Navali , Saman Tahouri .*

**AIM :** The purpose of this paper is to present a newly designed and manufactured arthrometer which permit an automated analysis of ACL competency.

**METHODS :** This arthrometer technology is based on the anterior drawer test but more specifically on the lachman test with innovation present at its construction. It provides precise evaluation of the knee ligamentous stability by applying automated and controlled tibial translation and objective knee joint laxity testing.

**RESULTS :** We have tested this arthrometer on 196 ACL deficient patients and measured the side to side difference in anterior tibial translation by applying an automated mechanical force. The side to side difference in tibial translation was measured in millimeters in different forces from 0 to 200 N.

**CONCLUSION :** The dynamic automated tests on each knee are done with a precision of 0.5 mm and provide a wide range of information such as the tibia/femur displacement differential and the slope of the curve related to tibial translation in increasing postero-anterior forces. This eventually leads to making a precise diagnosis of the state of knee ligaments (displacement differential) and knee stability (slope of the curves).

**KEYWORDS:** ACL, arthrometer, anterior tibial translation, lachman test.

**20 . TITLE : Evaluation of 3-Dimensional Profile of Asian Knee .**

*Author : Babak Otoukesh.*

**AIM :** Maintaining proper size and rotation of components of total knee arthroplasty is mandatory for optimal longevity. Ethical differences may affect fitness of the prostheses that were manufactured mainly based on Caucasian dimensions. This review aimed to evaluate 3- dimensional characteristics of distal femur and proximal tibia among Asian populations. Moreover rotational profile of distal femur was also assessed.

**METHODS :** Databases were searched and relevant studies were selected. Including criteria were: studies on Asian populations, studies on morphological and rotational characteristics of the knee joint and prostheses. Finally 21 studies were selected.

**RESULTS :** Based on the studies male subjects enjoy larger dimensions, while total configuration is proportionately similar to female at axial section. Some other studies in white populations or Asian populations found significant discrepancies among genders. Also it was indicated as anteroposterior size grows, aspect ratio shows downward inclination in both genders and in studied prostheses for Asian populations. In contrast to western Caucasian knees, there are some parameters in the Asian knees which decrease upon increasing the other parameters and the size of the knee. Finally females enjoyed greater value of these rotational values in majority of the studies.

**CONCLUSION :** Generally, it can be said that assumption of smaller knee in Asian relative to white population is more accurate on femoral side while tibial dimensions share more homogenous profiles.

**KEYWORDS:** Total Knee Arthroplasty; 3-dimensional Profile; Asian knee.

**21 . TITLE : Comparison Of Timing Of Core Muscles In Healthy Controls And Acl Reconstructed Patients While Landing .**

*Author : Vahid Mazloum .*

**AIM :** The aim of this study was to compare the core muscles activation patterns between healthy group and patients with ACL reconstruction (ACLR) during landing task.

**METHODS :** Fifteen males with ACLR and fifteen asymptomatic controls participated in this non-experimental cross-sectional case control study. Surface Electromyography of Gluteus medius, Erector Spine, and Internal Oblique muscles was recorded and onset latencies and time to peak latencies were assessed during landing. The time of foot contact was determined by a sensitive surface.

**RESULTS :** Onset time of all muscles during landing in the healthy group was significantly less than ACLR group ( $P<0.05$ ). Time to peak in healthy group was also significantly less than ACLR group ( $P<0.05$ ).

**CONCLUSION :** The preactivation onset time and time to peak of core muscles are altered in subjects with ACLR.

**KEYWORDS:** Timing, Electromyography, Core Muscles, Anterior Cruciate Ligament.

**22 . TITLE : Accuracy Of Preoperative Mri In Predicting Subscapularis Tendon Tear Based On Arthroscopic Diagnosis.**

*Authors : Hossein Saremi, Soheila Yusofi.*

**AIM :** to determine accuracy of MRI for detecting subscapularis tendon tear.

**METHODS :** during 2012 to 2014, results of MRI scan of patients who underwent arthroscopic repair for rotator cuff tear were interpreted by a radiologist and a shoulder surgeon ,then the results of these interpretation was compared to the video recording of the arthroscopic surgery of the patients.

**RESULTS :** All 16 patients whose MRI scan showed subscapularis tear, had subscapularis tear in arthroscopy resulting in perfect specificity. However MRI diagnosed only 16 of 41 patients who had subscapularis tear (39.2%), this resulted in an overall sensitivity of 39.2%, specificity of 100%, positive predictive value of 100% and accuracy of 70.59%.

**CONCLUSION :** MRI as a diagnostic modality can help to detect subscapularis tendon tears but False negative diagnosis rate is High compared to other rotator cuff tendons possibly because of special insertion topography

**KEYWORDS:** MRI, Subscapularis tendon tear, Accuracy.

**23 . TITLE :** Correction Of Hindfoot Alignment After Total Knee Arthroplasty In Patients With Severe Knee Varus Or Valgus Deformity.

*Authors : Gholamreza Azarria ,Hosseinali Hadi Mahmoed Jabalamoti ,Abolfazl Bagheri Fard Ahmadreza Behrouei, Amir Azmi.*

**AIM :** Knee and ankle deformities put abnormal stresses to each other during standing and ambulation. Patients with severe knee coronal deformity have compensatory deformities in their ankle and hindfoot to paingrade the foot. Persistence of these deformities in ankle and hindfoot after correction of knee deformity with arthroplasty, may produce abnormal stress to the knee and leads to patient dissatisfaction. The purpose of this study was to evaluate the effect of knee arthroplasty on hindfoot alignment in patients with severe knee varus or valgus deformity.

**METHODS :** Eighty four patients (84 knees) with primary osteoarthritis of the knee who were scheduled for total knee arthroplasty were enrolled in this study with inform consent. Exclusion criteria includedneuromuscular disease, secondary osteoarthritis of the knee and secondary deformities of the ankle (previous fracture and systemic arthritis).Knee deformity was measured with the use of preoperative long leg film. Knee deformity of more than 10 degree is considered severe. Standing long axial radiography of hindfoot were taken before and six month postoperatively. Anatomic axis of distal tibia and calcaneus were drawn and intersecting angle was measured as hindfoot deformity. Hindfoot valgus alignment was recorded by positive numbers and varus was recorded by negative numbers. Measured hindfoot angles were compared in pre- and postoperative radiographs. Data were analyzed by SPSS 20 .

**RESULTS :** Eighty four patients with the mean age of  $69.28 \pm 7.77$  years, 77.4% percent were female. Among these 77 patients (92%) had knee varus deformity and 7 patients (8 %) had valgus deformity. There were no significant difference in gender between two groups ( $p > 0.05$ ). There was no correlation between severity of knee deformity and hindfoot angle ( $p > 0.05$ ). Difference between mean hindfoot angle before and after surgery was statistically significant ( $P < 0.0001$ ).

**DISCUSSION & CONCLUSION :** Hindfoot alignment was significantly improves after total knee arthroplasty in patients with severe genu varum and genu valgum. Severity of knee deformity is not correlated with hindfoot alignment .

**KEYWORDS:** Hindfootalignment, Knee arthroplasty, Genu varum, Genu valgum .

**24 . TITLE :** Effect Of Zoledronic Acid And Vitamin E On Surgical-induced Femoral Head Osteonecrosis In Rabbit.

*Authors : Sina Aminizadeh, Kaveh Gharanzadeh, Amir Darbandi ,ShabnamNadjiati Mahsa Fadavi ghaffari, Tina Shooshbarizadeh.*

**AIM :** Femoral head osteonecrosis is a progressive disease with disabling outcomes in hip joint if not treated. This study was designed to compare the effects of zoledronic acid plus vitamin E versus zoledronic acid alone in femoral head osteonecrosis induced by surgical method in rabbits.

**METHODS :** 6 Japanese white adult male normal rabbits at 28-32 weeks old were underwent surgical femoral dislocation to devastate the femoral neck vessels; the femoral neck vessels were ligated. Next, the first 10 rabbits received Zoledronic acid alone that was injected at the 1st and the 4th week; the second group (10 rabbits) received the zoledronic acid that was injected 1st and the 4th week plus oral vitamin E that was added to the food(daily) for 12 weeks and the third group was considered as control group. The treatment process was persisted for 12 weeks and the radiographic and postmortem pathological assessments were performed. The Ficat classification, Epiphyseal Quotient, new bone formation, and residual necrotic bone were assessed. The results were analyzed by statistical chi-square, paired t-tests, independent t-test, Fisher's test and  $p$ -value  $< 0.05$  was considered significant.

**RESULTS :** There were significant statistical difference between the combination therapy group with control group for Ficat at 12th weeks ( $p$ -value=0.048) but there was no significant statistical difference between monotherapy and combination therapy groups for Ficat at 12th weeks. Also, both treated groups with control group had significant statistical difference for RNB ( $p$ -value=0.015). There were no statistically significant differences between three groups for Ficat at 6th week, EQ at 6th and 12th week and NBF ( $p$ -value  $\geq 0.05$ ) in comparing the three groups.

**CONCLUSION :** Although zoledronic acid therapy along with vitamin E could improve some radiologic and pathological indices related to femoral head osteonecrosis, vitamin E showed relative impact.

**KEYWORDS:** Zoledronic acid, Vitamin E, Femoral head osteonecrosis.

**25 . TITLE : Surgical Treatment Of Chronic Patellar Tendon Rupture; A Case Series Study.**

*Authors : Salman Ghaffari, Mahmoud Jabalameli, Abolfazl Bagherifard, Hosseini Hadi Mohammad mujeb Mohseni, Amin Yossefzadeh.*

**AIM :** Early detection and treatment of extensor mechanism rupture is essential for a long-term functional knee joint. In chronic cases quadriceps muscle retraction and contracture makes surgery difficult and results less predictable. The purpose of this study was to evaluate outcomes in cases of late repaired patellar tendon ruptures.

**METHODS :** This study included patients with chronic patellar tendon rupture who had been operated on in our hospital from 2006 to 2013.

**RESULTS :** A total of ten patients were evaluated, presenting twelve cases of chronic patellar tendon rupture. Patients had a mean age of 34.4 years (range 18-58). Seven cases were caused by traffic accident and three by a fall. The mean length of time from injury to surgery was 23 months (range 3-132). The mean time of follow-up was 6.2 years (range 3-9). Cerclage wire reinforcements were applied in nine of the knees and the other three knees had fiber wire reinforcement. Tendon graft augmentation was applied in ten of the knees; six with semitendinosus and gracilis autograft, two with semitendinosus autograft, one with an Achilles tendon allograft and one with a tibialis anterior allograft. Means for preoperative/postoperative active knee range of motion, extension lag, subjective International Knee Documentation Committee score and modified Cincinnati scores were 81/117, 32/2, 22.7/84.5 and 24/87 respectively. Wire breakage was seen in all nine knees but wires were removed in only two symptomatic cases.

**CONCLUSION :** Good to excellent results were obtained in terms of functioning with operative treatment of chronic patellar tendon rupture. Direct repair with autogenous or allogenic graft augmentation and cerclage wire reinforcement and postoperative cast immobilization is recommended.

**KEYWORDS:** Chronic Patellar tendon rupture; International Knee Documentation Committee score; Modified Cincinnati score .

**26 . TITLE : Open Patella Periprosthetic Fracture After Total Knee Replacement: A Case Report And Review Of Literatures**

*Authors : Mohammad javad Dehghani  
Seyyed mohammad javad Moravveji, Hojjat Askari  
Ahmad Ramezanzpou.*

**AIM :** Periprosthetic fracture after total knee arthroplasty is one of the most common reasons of revision arthroplasty but periprosthetic fracture of the patella has been shown to be very rare. In presented paper, we report a 60 years old female with open patellar periprosthetic fracture after total knee replacement .

**METHODS :** The patient is a 60 years old female that 5 months after total knee replacement due to falling, she suffered open patella fracture. The patient was placed under the fixation of the patella and wound repair after irrigation and debridement in the operating room.

**RESULTS :** Patellar periprosthetic fracture has been reported very rare and the incidence after total knee arthroplasty is about 0.5 to 3 percent. There are two known etiologies of periprosthetic fractures of the patella in different studies, the first one is stress fracture due to osteonecrosis and the second one is trauma which is less common. In the management of these specific fractures one should always consider following factors: the amount of displacement, extensor mechanism function, patellar implant stability and bone stock. In this case we presented here, a patient with a displaced open fracture was placed under the ORIF of patella and soft tissue repair .

**DISCUSSION & CONCLUSION :** Despite the fact that operative management of periprosthetic fractures of the patella has high rate of complications and poor outcome, it can be considered for patients with open periprosthetic fractures of the patella specially when the extensor mechanism is compromised.

**KEYWORDS:** Preprosthetic fracture, open fracture, preprosthetic patellar open fracture .

**27 . TITLE : Comparing The Vmo Muscle Activity During Quadriceps Setting Exercise In Both Condition Of With And Without Ankle Dorsiflexion.**

*Authors : Fatemeh Menatnia ,Ali ushraf Jamshidi,  
javad sarrafzadeh, Zahra Menatnia.*

**AIM :** quadriceps muscle contains four muscles that are located near one another and on the front of the femur. Their role is to extend the knee joint and plays an important role in standing up and walking. Most of the quadriceps muscle weakens after a sustained injury or a knee or thigh surgery, which reduces the stability of the knee. Typically, a specific area of the quadriceps muscle called the vastus medialis oblique (VMO) weakens, and in certain situations is unable to function appropriately. The VMO muscle plays an important role in straightening the knee within the terminal domain and keeping the patellar stable in front of the knee. Moreover, the VMO muscle is one of the



## POSTERS

important factors in knee stability during weight bearing. Strengthening the quadriceps muscle, especially after knee surgery, is very important as these muscles are structures that support the knee and if they lack enough strength it will cause problems for the individual. Nowadays, one of the most common exercises used to strengthen the muscles in front of the thigh is quadriceps setting. However, there is still no agreement on the best way to practice this exercise in relation to the state of the ankle. The aim of this study is to situate the ankle in the most appropriate state during the exercise in order to achieve the best possible outcome. One of the best clinical tools for basic and clinical research is electromyography, and one of the major applications of the kinesiology EMG is the evaluation of muscle activity during different movements. Therefore, in this study, using electromyography instruments, we have tried to compare the activity of the VMO muscle during quadriceps setting in two conditions of with and without ankle dorsiflexion.

**METHODS :** 30 healthy individuals (15 women and 15 men), with no history of surgery and knee pain, between the ages of 20 to 40 years, were enrolled in this study. Initially, a MVIC was taken in a sitting position with a 90-degree knee flexion, in order to normalise the dominant foot of the participants. Subsequently, an electromyography of the VMO and anterior tibialis was taken during quadriceps setting, with and without ankle dorsiflexion, in a long sitting position, with a 10 cm roll placed below the knee. In this study, adhesive AG-AGCL surface electrodes with a diameter of 1 cm and placed 2 cm apart, and the ground electrode laterally positioned, were used. In order to remove noise, the electrodes and wires were completely fixed with tape and strapped, and the wires were placed in a heart, symmetrical shape. Additionally, all unnecessary electrical appliances, even the lamps, were turned off. Firstly, all of the RMS data was taken and then a section of the graph that could represent a total of 1 second was separated from the chart and the mean was obtained. The result was then normalised with MVIC. The duration of the recording time in each of the three stages was 10 seconds. 2-3 seconds before and after performance of activities the individuals remained still in order to detect noises such as city electricity and etc.

**RESULTS :** After RMS analysis of the data (one second), statistical analysis was done using SPSS version 19, and considering the significance level of 0.05 it showed that the distribution of data was normal and there was a significant difference between the two stages ( $p = 0.011$ ).

**CONCLUSION :** This study was an attempt to identify the effect of ankle dorsiflexion on the VMO muscle in healthy individuals, and comparing this with the neutral position of the ankle. Based on the findings of this study, the combination of ankle dorsiflexion during quadriceps setting exercises can have a stronger effect on the VMO muscle when compared to the neutral position of the ankle.

**KEYWORDS:** vastus medialis oblique (VMO), quadriceps setting exercise, ankle dorsiflexion, kinesiology EMG .

## 28 . TITLE : Mid -term Clinical Outcome Of Arthroscopic Repair Of Isolated Subscapularis Tendon Tear .

*Authors : Hossein Saremi ,Shervin Bashiri.*

**AIM :** to evaluate clinical outcome of arthroscopic repair for isolated subscapularis tendon tears with mid term followup.

**METHODS :** All patients who had isolated lafosse type 3 or 4 subscapularis tendon tear were repaired arthroscopically from 2011 to 2015 in our center,clinical results were evaluated using UCLA score, Quick DASH score ,VAS, press belly test and lift off test before operation and at least 2 years followup.the data was analized using SPSS16.

**RESULTS :** 7 patients (2 women and 5 men) with arthroscopic isolated subscapularis tendon repair had at least 2 years followup.mechanism of injury was trauma in 6 cases..UCLA score increased from10.71 to 33.28, quickDASH score decreased from 38.28 to 7.56, VAS also decreased from 4.57 to 0.57. press belly test and lift off test were normal in all cases.

**CONCLUSION :**Mid term result ofArthroscopic repair for isolated subscapularis tendon tear is satisfactory. Although the number of cases is limited as other studies because of the incidence of isolated tears,arthroscopic repair is a surefire way to treat the patients .

**KEYWORDS:** Isolated subscapularis tendon tear,shoulder arthroscopy,clinical outcome .

## 29 . TITLE : Treatment Of Long Head Of Biceps Tendon Lesions Together With Rotator Cuff Tears: Which Method Is Preferred? Tenotomy Or Tenodesis?

*Authors : Mohsen Mardani-kivi ,Mahmoud Karimi Moharakeh Sohrab Keyhani, Mohammad Hossein Ebrahimi-zadeh, Zahra Haghparast Ghahim-Linulahi .*

**AIM :** Long head of biceps tendon (LHBT) lesions are associated with rotator cuff tears and in large tears surgery is the treatment of choice. Here, we aimed to evaluate outcomes of tenotomy and tenodesis in such cases.

**METHODS :** In this randomized clinical trial, patients aged 45-60 years who were candidates for arthroscopic treatment of rotator cuff tears with at least one positive biceps test before surgery were enrolled. Patients were allocated in tenotomy or tenodesis groups using random block. Therapeutic outcomes were investigated by evaluation of occurrence of Popeye deformity, patient's satisfaction based on visual analog scale (VAS), shoulder function according to the Constant score and simple shoulder test (SST) and pain intensity based on numerical rating scale (NRS) were measured before treatment and at 6 months, one and two years after operation. All data analyzed using SPSS software version 20.

**RESULTS :** Both Popeye deformity and biceps brachii cramping were significantly higher in tenotomy group. Values of NRS, SST, VAS of patient's satisfaction, and Constant score significantly changed after operation as decrease in NRS and increase in all three others. However, only VAS of patient's satisfaction significantly differed between two groups just at 12 and 24 months post-operation. Only age, sex and dominance of involved limb had significant association with patient's satisfaction. Indeed, younger female patients with involvement of recessive limb had significant higher satisfaction ( $P < 0.05$ ).

**CONCLUSION :** Both methods produced good clinical outcomes. Although patient satisfaction was higher in tenodesis group, no significant differences existed in functional outcomes.

**KEYWORDS:** Long head of biceps tendon lesions; Rotator cuff tears; Tenodesis; Tenotomy; Surgical method; Tendon lesions

### 30 . TITLE : Knee Hydatosis; A Case Report.

*Authors : Arush Sharafat varziri , Shahin Mirkarimi  
Mohammad naqhi Tahmasebi .*

**AIM :** Hydatosis is a parasitic infection caused by the larval stage of echinococcus species. Its usually affects liver, spleen and lungs. The incidence of bone Hydatosis is about 1 to 2.5%. primary bone Hydatosis develops when the scoleces are localized in the bone, cysts within the bone may remain asymptomatic for years. The diagnosis of bone Hydatosis is difficult and easily overlooked unless there is a strong element of suspicion.

**METHODS :** A 37 years old woman has been admitted with pain and swelling in her right knee. on physical examination there was tenderness on palpation of medial aspect of the knee. In the laboratory tests no pathology was determined in routine haemogram and biochemical tests. Plain radiographs demonstrated a large lytic lesion with cortical erosion in the medial condyle of the distal femur. Magnetic resonance

imaging(MRI) was done which reported as pigmented villonodular synovitis. Magnetic resonance imaging (MRI) revealed a large altered signal intensity lesion involving medial condyle of femur and multiple peripheral cysts and low signal intensity lesion in the suprapatellar pouch and intercondylar notch. The patient underwent diagnostic arthroscopy. Debridement of the hypertrophied synovium in the suprapatellar pouch and intercondylar notch was done. after that, diagnostic incisional biopsy and following intraoperative cyst curettage of lytic lesion of the medial condyle was performed. The histopathological examination was compatible with hydatid cyst.no signs of echinococcal disease were found in abdominal ultrasonography and computerized tomography(CT)of thorax. Oral albendazole 10mg/kg/day was prescribed for three months. Definitive surgery was performed after three months. Curettage of the lytic lesion of medial condyle was done via subvastus medial arthrotomy and the defect was filled with bone cement.

**RESULTS :** Our patient was managed with initial oral albendazole for three months followed by curettage and bone cementing of the lesion. Oral albendazole was prescribed for 6 months after the definitive surgery. Functional outcome was excellent and she can walk without pain and there was no evidence of recurrence.

**CONCLUSION :** In endemic regions such as Iran, hydatid disease should be considered as the differential diagnosis of soft tissue masses or destructive bone lesions. In early stages of the disease it can be treated with curettage and bone cementing.

**KEYWORDS:** Bone hydatosis.knee

### 31 . TITLE : Mesenchymal Stromal Cells Implantation in Combination with Platelet Lysate Product Is Safe for Reconstruction Of Human Long Bone Nonunion.

*Authors : Narges Labibzadeh ,Nasser-Aghdani,  
Mohsen Emadeddin,Seyedeh Esmat Housseini,  
Reza Moghadassali ,Soura Maraspour,Vajihesh Azmian.*

**AIM :** Nonunion is defined as a minimum of 9 months since injury without any visible progressive signs of healing for 3 months. Recent literature has shown that the application of mesenchymal stromal cells is safe, in vitro and in vivo, for treating long bone nonunion. The present study was performed to investigate the safety of mesenchymal stromal cell (MSC) implantation in combination with platelet lysate (PL) product for treating human long bone nonunion.

**METHODS :** In this case series clinical trial, orthopedic surgeons visited eighteen patients with long bone nonunion, of whom 7 complied with the eligibility criteria. These patients received mesenchymal stromal cells (20 million cells implanted once into the nonunion site using a fluoroscopic guide) in

combination with PL product. For evaluation of the effects of this intervention all the patients were followed up by taking anterior-posterior and lateral X-rays of the affected limb before and 1, 3, 6, and 12 months after the implantation. All side effects (local or systemic, serious or non-serious, related or unrelated) were observed during this time period.

**RESULTS :** From a safety perspective the MSC implantation in combination with PL was very well tolerated during the 12 months of the trial. Four patients were healed; based on the control X- ray evidence, bony union had occurred.

**DISCUSSION & CONCLUSION :** Results from the present study suggest that the implantation of bone marrow-derived MSCs in combination with PL is safe for the treatment of nonunion. A double blind, controlled clinical trial assess the efficacy of this treatment (Registration Number: NCT01206179).

**KEYWORDS:** Fractures Ununited, Mesenchymal Stromal Cells, Platelet Lysate.

**32 . TITLE : Arthroscopic Bridge Technique for PCL Avulsion: Surgical Technique and Key Points.**

*Authors : Hamidreza Aslani, Seyed Taghi Nourbakhsh Fateme Mirzaee, Fateme Bahramian, Zohreh Zafarani Mohammad Ali Sazegari, Ardesheer Alilouost.*

**AIM :** PCL avulsion occurs in the setting of high-energy trauma, motorcycle accidents, and occasionally in lower-energy sports-related injuries in young and active individuals. Complete arthroscopic procedure is an effective and safe method in fixing the PCL avulsion fracture. The aim of this study describes this technique and presents the results of our patients after this type of surgery.

**METHODS :** Three consecutive patients with the diagnosis of PCL avulsion fracture were operated using the arthroscopic bridge technique.

**RESULTS :** All were satisfied and returned to the activities prior to injury. This technique can be considered as a safe and effective method for fixation of PCL avulsion, which allows active mobilization with lowered risk of complications.

**DISCUSSION & CONCLUSION :** We conclude that that an arthroscopic bridge technique is likely to provide good and acceptable results with anatomical reduction of the fragment while it is a safe and effective method. Moreover, the arthroscopic bridge technique minimizes the risk of neurovascular injuries.

**KEYWORDS:** Arthroscopic bridge technique, Avulsion, Posterior cruciate ligament, Repair.

**33 . TITLE : Anterior Referencing Vs Posterior Referencing Sizing In Total Knee Arthroplasty: As Engineering Point Of View .**

*Author : Meysam Karimi .*

**AIM :** Currently, huge numbers of total knee arthroplasty (TKA) have been done in the world annually. Numerous companies have launched their products to the market in last decades and have optimized their implants and also instruments to increase the patients and surgeons satisfaction. One of the most important parts during TKA surgery is femoral Anterior/Posterior sizing that has two main methods, posterior referencing (PR) and anterior referencing (AR). Although these approaches and their features and benefits have been studied as medical point of view, this is the first time that these techniques have been reviewed based on engineering view. The aim of our study is evaluation of difference between PR and AR in the femoral sizing guide and also femoral 4 in 1 cutting blocks. Also the effect of PR and AR on essential issues including flexion gap balancing, anterior notching and overstuffing, posterior condyle offset adjustment have been discussed.

**METHODS :** A review on the available system take placed and approaches and instruments which are used for femoral sizing and cutting have been evaluated.

**RESULTS :** Among six available implants and its' instruments evaluated based on sizing guide and 4 in 1 cutting block differences and its effect on femoral preparation.

**CONCLUSION :** In conclusion, both PR and AR have its own strengths and weaknesses. AR shows more ability in flexion gap balancing while PR has superior potential in anterior notching/overstuffing avoiding and posterior condyle offset adjustment. Although each approach may have few weaknesses, companies sometimes introduce exclusive instruments to solve the each possible problem. Totally, surgeons' familiarity with each techniques and related instruments can help them to do the best for their patients.

**KEYWORDS:** Total knee arthroplasty, Anterior referencing, Posterior referencing.

**34 . TITLE : Arthroscopic Management Of Femoroacetabular Impingement.**

*Author : Masoud Mokhtari, Sh Shirsani MK Emami meibodi.*

**AIM :** The aim of this study was to analyze the early outcomes of arthroscopic management of femoroacetabular impingement (FAI).

**METHODS :** Fifteen patients with radiographic and clinical demonstrated FAI in Baghyatallah hospital's polyclinic, imported in this study. They were managed with hip

arthroscopy. Outcomes were measured with the FAHER, and FADIR tests, modified Harris Hip Score and pain score on a visual analog scale preoperatively and postoperatively at 12 weeks and 6 months. Preoperative and postoperative radiographic alpha angles were obtained to aim the adequacy of proximal femoral osteoplasty.

**RESULTS :** There were 3 men and 10 women with half year's follow-up. The mean age was 36.3 years. Pincer impingements and combined forms were excluded. Arthroscopic osteochondroplasty of the femoral head neck accomplished. Acetabular chondroplasty with shaving carried for three cases. A comparison of preoperative scores with those obtained at 2 steps follow-up showed a significant improvement ( $P<0.02$ ) for all outcomes measured: Harris Hip Score (65.5 vs 88.4), visual analog score for pain (7.3 vs 2.3 cm) and positive FADIR test (100% vs 15%). The alpha angle was also significantly improved after resection osteoplasty (57.1 vs 48 degrees).

**DISCUSSION & CONCLUSION :** Arthroscopic management of cases with FAI results in significant improvement in outcomes measures in 6 months follow up period.

**KEYWORDS:** arthroscopic management, Femoroacetabular impingement.

**35. TITLE :** Evaluation of Autogenous Osteochondral Grafting for Treatment of Osteochondritis Dissecans , mid term results .

*Author : Dr Sohrab Keyhani, Dr Mehran Soleymanlu  
Dr Mohammadreza Abasian, Dr Seyed Morteza Kazemi*

**OBJECTIVS :** Although some surgical techniques have been described for the operative treatment of unstable Osteochondritis dissecans of the knee, but outcomes are variable and aren't satisfying totally. The aim of the present study is to evaluate the outcomes of autogenous osteochondral grafting for OCD of the knee.

**METHODS :** In a case series study, from June 2014 to July 2015, 16 patients with stage II-IV OCD (International Cartilage Repair Society [ICRS]) of the femoral condyle were investigated. Surgical intervention considered in cases of stage III (4 cases) and IV (2 cases) and in stage II (10 cases) ones that were non responsive to Conservative treatment. At the initial and final visits, the IKDC, Lysholm score and Tegner activity scale were evaluated.

**RESULTS :** The mean preoperative IKDC score (53.4) increased significantly following surgery (84.3) ( $p<0.001$ ). Based on the IKDC grading system, before the operation, the knee status was graded as nearly normal, abnormal, and severely abnormal in 4, 10, and 2 patients, respectively. At

final post surgical follow up, 15 normal and 1 abnormal knee were documented ( $p<0.001$ ). At the final visit, all of patients (except one) were asymptomatic and returned to their previous activity levels.

**CONCLUSION :** Surgical treatment of unstable OCDs using autogenous osteochondral graft shows successful outcomes. In addition to reliable fixation it can enhance healing and convert an uncontained lesion to contained one with healthy cartilage .

**KEYWORDS:** arthroscopy-osteochondritis dissecans-mosaicplasty .

**36. TITLE :** Arthroscopic Treatment Of Diffuse Pigmented Villonodular Synovitis Of The Knee Complete Synovectomy And Septum Removal- Midterm Results.

*Author : Dr Sohrab Keyhani, Dr Mehran Soleymanlu  
Dr Seyed Morteza Kazemi.*

**OBJECTIVS :** The purpose of this study was to evaluate and describe the clinical results and outcomes of complete arthroscopic synovectomy through the four arthroscopic portals in the knee affected by diffuse pigmented villonodular synovitis.

**METHODS :** Between 2009 and 2014, 19 patients (17 men and 10 women) with diffuse form of pigmented villonodular synovitis of the knee were enrolled in the study after qualification. The clinical diagnosis was confirmed by MRI and post-surgery pathology. All patients underwent complete synovectomy through posteromedial, posterolateral, anteromedial and anterolateral portals. Each patient was evaluated before treatment and minimum of 2 years follow-up according to clinically, radiographically and subjectively.

**RESULTS :** Patients were followed up for a minimum of 2 years (range 24 - 79 months). Both Lysholm score and IKDC scores were significantly increased in all cases. No case of recurrence, infection, joint stiffness or neurovascular lesions were seen.

**CONCLUSION :** This study showed that a well done arthroscopic synovectomy is safe and gives good clinical outcome with low recurrence rate.

**KEYWORDS :** arthroscopy-PVNS-synovectomy .

# IRAN KISH ISLAND 2018



info@iskast.com  
iskastoffice@gmail.com



Telefax: +9821 88 08 42 18



www.iskast.ir